

# Mechanisms of Vascular Calcification in Chronic Kidney Disease

Sharon M. Moe and Neal X. Chen

Department of Medicine, Indiana University, Indianapolis, Indiana

## ABSTRACT

Vascular calcification is common in chronic kidney disease and associated with increased morbidity and mortality. Its mechanism is multifactorial and incompletely understood. Patients with chronic kidney disease are at risk for vascular calcification because of multiple risk factors that induce vascular smooth muscle cells to change into a chondrocyte or osteoblast-like cell; high total body burden of calcium and phosphorus due to abnormal bone metabolism; low levels of circulating and locally produced inhibitors; impaired renal excretion; and current therapies. Together these factors increase risk and complicate the management of vascular calcification.

*J Am Soc Nephrol* 19: 213–216, 2008. doi: 10.1681/ASN.2007080854

Calcium is an abundant element in nature. It is a major component of sedimentary rock that covers 75% to 80% of the Earth's surface. Bone, another form of a rock, serves as the storage unit for 99% of total body calcium, predominantly in the form of a calcium phosphate moiety called hydroxyapatite. Calcium salts are also found occasionally outside bone in a variety of tissues; this is broadly termed extraskeletal calcification. In these extraosseal sites, calcium collects in multiple forms, including hydroxyapatite, magnesium whitlockite, and amorphous calcium phosphate. Some of this calcification occurs in the setting of cellular necrosis. Other forms of extraskeletal calcification adhere to damaged proteins, so called dystrophic calcification. Finally, cells with unexpected osteoblastic potential may abnormally lay down some forms of calcification, especially in the arterial wall of blood vessels.

Bone forms in children through mineralization of cartilage, a process called modeling, and then continues to re-

model as we age in response to daily mechanical and hormonal stresses. The latter involves not just bone formation by osteoblasts, but bone resorption by osteoclasts, remodeling haphazard or woven bone into structurally sound lamellar bone.

The pathogenesis of arterial calcification is likely a hybrid process of tightly regulated normal bone modeling and the purely physicochemical deposition of mineral without cellular involvement. Arterial calcification is not a new observation—it was identified by computerized tomography (CT) scan in the recently discovered 'ice man' from 5000 yr ago.<sup>1</sup> Alfrey and colleagues demonstrated in 1979 that arteries of patients with chronic kidney disease have more calcification than arteries from age-matched healthy individuals.<sup>2</sup> So why is there so much interest in arterial calcification in patients with chronic kidney disease nearly 30 yr later?

There are several reasons. First, we now have a clear idea in the general population that calcification of both intimal

atherosclerotic lesions and the medial vessel layer are associated with cardiovascular morbidity and mortality.<sup>3,4</sup> Similar, albeit less robust data also exists for stage 5 chronic kidney disease.<sup>5,6</sup> Second, there is now better evidence that vascular smooth muscle cells can become chondrocyte or osteoblast-like and lay down and mineralize collagen and non-collagenous proteins in arteries.<sup>7</sup> This critical observation suggests therapeutic arrest of this cellular transformation may be a viable treatment approach. Third, over 20 null mutations in mice have arterial calcification.<sup>8</sup> This confirms that key proteins regulate or prevent arterial calcification. Fourth, there is increasing recognition of a link between chronic kidney disease and bone and arterial calcification in the general population. Simply put, the less mineral in bone, the more is seemingly in arteries.<sup>9</sup> Lastly, we now know some of our well-intended interventions to treat renal osteodystrophy accelerate arterial calcification. Indeed, management of chronic kidney disease patients can sometimes trap both the patients and the physicians between a rock and a hard place.

Clinically, arterial calcification is detected through a number of techniques including plain radiographs, tomogra-

Published online ahead of print. Publication date available at [www.jasn.org](http://www.jasn.org).

**Correspondence:** Dr. Sharon M. Moe, Professor of Medicine, Department of Medicine, Indiana University, 1001 W. 10th Street, OPW 526, Indianapolis, IN 46202. Phone: 317-278-2868; Fax: 317-278-2860; E-mail: [smoe@iupui.edu](mailto:smoe@iupui.edu)

Copyright © 2008 by the American Society of Nephrology

phy, scintigraphy, and CT scan. More recent technologic advances have led to ultrafast CT scans [electron beam CT (EBCT) and newer multislice CT (MSCT)] that use electrocardiographic gating to allow heart imaging only in diastole, thus avoiding motion artifact. These techniques permit reproducible quantification of calcification in coronary arteries and the aorta, and therefore inform our recognition of vascular deposition. Unfortunately, these techniques do not allow differentiation of medial from intimal calcification. Braun *et al.*<sup>10</sup> first demonstrated that coronary artery calcification by EBCT increases with advancing age in patients on dialysis, and that calcification scores were two- to five-fold greater in dialysis patients than age-matched controls with normal kidney function and angiographically proven coronary artery disease, data reproduced by many methods in cohorts around the world. Incident dialysis patients followed for 5 yr demonstrate that coronary artery calcification scores of more than 400 by EBCT are associated with increased mortality.<sup>5</sup> In addition, valvular calcification<sup>11</sup> and peripheral artery calcification (either intimal or medial)<sup>6</sup> are also associated with increased mortality. A recent study comparing the sensitivity and specificity of various measures of arterial calcification found either a plain lateral lumbar film to assess aorta calcification or echocardiographic evidence of valvular calcification are highly predictive of coronary artery calcification,<sup>12</sup> suggesting a common pathogenic process.

### The Pathophysiology of Vascular Calcification

Although calcification can occur in the arterial intima adjacent to plaques and in the medial layers, it is not clear if these forms of calcification are identical, or if they have different inciting factors leading to a common pathogenic mechanism that parallels bone formation. Transcription factors such as Cbfa1/RUNX2 and MSX-2, critical for normal bone development, have been identified in cells surrounding human arterial calcification in both the general population and in

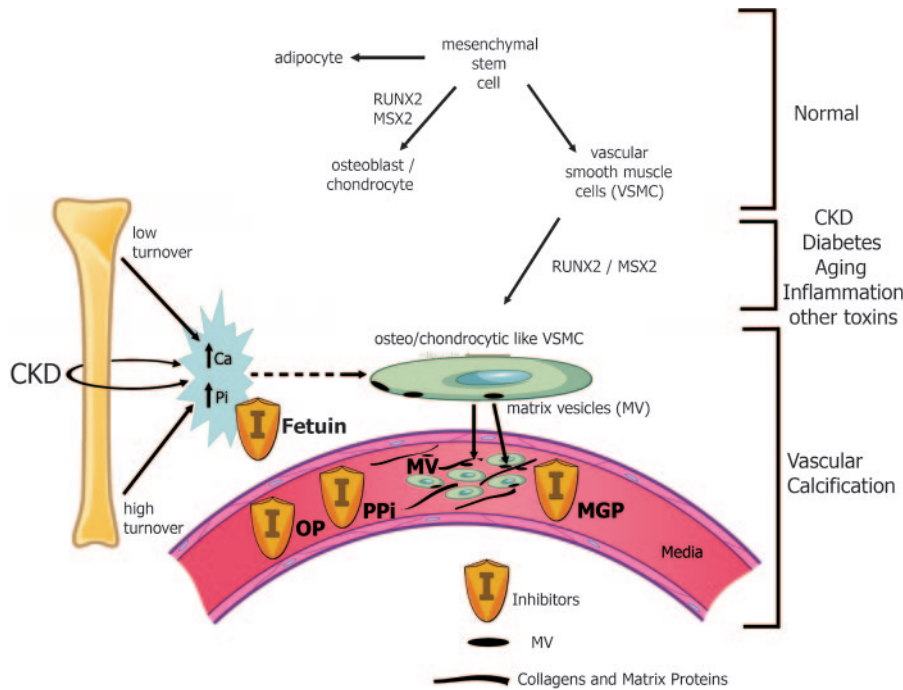
chronic kidney disease patients, in animal models, and *in vitro*.<sup>7</sup> The bone proteins osteonectin, osteopontin, bone sialoprotein, type I collagen, and alkaline phosphatase have also been identified in multiple sites of extraskeletal calcification. In cell culture, vascular smooth muscle cells and vascular pericytes are capable of producing these same bone-forming transcription factors and proteins, and can be induced to do so with high concentrations of phosphorus, uremic serum, high glucose, oxidized lipids, cytokines, and several other factors.

Vascular smooth muscle cells that express these proteins are capable of forming mineralized nodules in cell culture experiments in the presence of phosphorus, either sodium phosphate or as a phosphate donor  $\beta$ -glycerophosphate that is cleaved to phosphorus by membrane-bound alkaline phosphatase. Thus, in addition to calcium, phosphorus is also a critical element of calcification both in bone<sup>13</sup> and in blood vessels, and the two are additive in their effects on *in vitro* vascular calcification.<sup>14</sup> For mineralization to occur *in vitro*, there is a need for cellular transformation and access to mineral. If one raises the mineral concentration high enough in culture media it will spontaneously precipitate, even in the absence of cells—the so-called ‘physicochemical’ deposition that is highly pH dependent. Various proteins can inhibit this physicochemical component of vascular calcification (see below). As recently reviewed, these data question the usefulness of the long argued concept of a calcium x phosphorus (Ca x P) product in blood as predictive of extraskeletal mineralization in patients with chronic kidney disease.<sup>15</sup> Indeed, this concept of a ‘safe Ca x P’ product, has given physicians a convenient way to analyze their patient’s monthly labs, but is not based on scientific data, and the risk associated with a given Ca x P product depends on the patient’s existing arterial disease, abnormal mineral homeostasis, and the availability of inhibitors of mineralization.

Uremic animal models of arterial calcification complement our clinical and *in vitro* work and have helped to charac-

terize the types of abnormalities that are important. These animal models can be broadly classified into five groups supporting the complex pathogenesis outlined in Figure 1: animals with hyperphosphatemia due to chronic kidney disease and high phosphorus diet, or those having genetic defects that impair renal excretion of phosphorus (Klotho or FGF-23, for example), animals made hypercalcemic with toxic doses of vitamin D, animals with atherosclerosis made uremic (ApoE and LDL receptor null mice), animals with abnormal bone remodeling (osteoprotegerin null mice), and animals with defects in inhibitors such as matrix Gla protein. Importantly, in these same animal models, arterial calcification can be prevented or reduced by therapies that normalize serum phosphorus (phosphate binders or low phosphate diet), correct secondary hyperparathyroidism (calcimimetics, and in some studies, vitamin D analogues), and by therapies that inhibit bone turnover, (bisphosphonates, osteoprotegerin, a vacuolar ATPase osteoclast inhibitor, and bone morphogenic protein 7). These findings provide strong evidence that hyperphosphatemia and calcium load are key risk factors, and that impaired bone remodeling leads to vascular calcification, confirming the link between abnormal bone remodeling and arterial calcification that exists in humans in the general population and in patients with chronic kidney disease.<sup>9</sup> It appears in patients with chronic kidney disease that both extremes of bone remodeling, low turnover (adynamic bone) and hyperparathyroid bone, may accelerate vascular calcification by not allowing calcium or phosphorus into bone, or resorbing it out of bone, respectively.

Interestingly, not all dialysis patients develop arterial calcifications, despite similar exposure to these risk factors, and importantly, do not develop calcification with increased duration of dialysis.<sup>5,7</sup> These findings imply there are protective factors, either in blood vessels or in the circulation, or both. If human serum is added to a solution containing high calcium and phosphorus, with or without cells, calcification is inhibited. Thus, se-



**Figure 1.** Normally, mesenchymal stem cells differentiate to adipocytes, osteoblasts, chondrocytes, and vascular smooth muscle cells (VSMC). In the setting of chronic kidney disease, diabetes, aging, inflammation, and multiple other toxins, these VSMC can dedifferentiate or transform into osteo/chondrocytic-like cells by upregulation of transcription factors such as RUNX-2 and MSX2. These transcription factors are critical for normal bone development and thus their upregulation in VSMC is indicative of a phenotypic switch. These osteo/chondrocytic-like VSMC then become calcified in a process similar to bone formation. These cells lay down collagen and noncollagenous proteins in the intima or media and incorporate calcium and phosphorus into matrix vesicles to initiate mineralization and further mineralize into hydroxyapatite. The overall positive calcium and phosphorus balance of most dialysis patients feeds both the cellular transformation and the generation of matrix vesicles. In addition, the extremes of bone turnover in chronic kidney disease (low and high or adynamic and hyperparathyroid bone, respectively) will increase the available calcium and phosphorus by altering the bone content of these minerals. Ultimately, whether an artery calcifies or not depends on the strength of the army of inhibitors (I) standing by in the circulation (fetuin-A) and in the arteries (PPI = pyrophosphate, MGP = matrix Gla protein, and OP = osteopontin as examples).

rum contains numerous inhibitors of calcification. The most abundant of these is fetuin-A, a reverse acute-phase reactant that acts as a ‘vacuum cleaner’ to rid plasma of excess calcium and phosphorus molecules. Levels of fetuin-A go down during inflammation, and low levels in dialysis patients are associated with vascular and valvular calcification and death.<sup>16</sup> Matrix Gla protein, pyrophosphate, and osteopontin are also local inhibitors of calcification. It is certainly likely other inhibitors exist as well. The importance of calcification inhibitors is demonstrated by the profound pheno-

type and site specificity of vascular calcification that occur in mice with null mutations, suggesting that, similar to bone,<sup>13</sup> calcification would proceed unabated if not regulated by these inhibitors. Different anatomic sites may have a unique profile for these modulators.

**Conclusions**

There are many underlying causes of vascular calcification that initiate the process by transforming vascular smooth muscle cells to a chondrocyte or osteoblast-like cell, including hyperphosphatemia, uremia, hyperglycemia, and

other metabolites. This process is accelerated in a setting of high calcium, high phosphorus, and abnormal bone remodeling, raising the risk of vascular calcification in dialysis patients. In addition, deficiencies in circulating or locally produced inhibitors of calcification, or a relative absence of inhibitors for a given level of calcium or phosphorus, modulate calcification. As shown in Figure 1, this complex pathogenesis is still not completely understood and its prevention will no doubt require a multi-faceted approach. Importantly, differentiating what protects some patients, but not others, may ultimately offer the most important clues of all.

**ACKNOWLEDGMENTS**

Dr. Sharon Moe is supported by NIH grant NIH K24 DK002775 and the Veterans Administration. She is a consultant and has grant support from Genzyme, Amgen, Shire, Abbott, and INEOS. Dr. Chen has grant support from Genzyme and a NIH grant NIH K01 DK64766.

**DISCLOSURES**

None.

**REFERENCES**

1. Murphy WA, Jr., Nedden Dz D, Gostner P, Knapp R, Recheis W, Seidler H: The iceman: discovery and imaging. *Radiology* 226: 614–629, 2003
2. Ibels LS, Alfrey AC, Huffer WE, Craswell PW, Anderson JT, Weil, R, 3rd: Arterial calcification and pathology in uremic patients undergoing dialysis. *Am J Med* 66: 790–796, 1979
3. Lehto S, Niskanen L, Suhonen M, Ronnema T, Laakso M: Medial artery calcification. A neglected harbinger of cardiovascular complications in non-insulin-dependent diabetes mellitus. *Arterioscler Thromb Vasc Biol* 16: 978–983, 1996
4. Schmermund A, Mohlenkamp S, Erbel R: Coronary artery calcium and its relationship to coronary artery disease. *Cardiol Clin* 21: 521–534, 2003
5. Block GA, Raggi P, Bellasi A, Kooienga L, Spiegel DM: Mortality effect of coronary calcification and phosphate binder choice in incident hemodialysis patients. *Kidney Int*

- 71: 438–441, 2007
6. London GM, Guerin AP, Marchais SJ, Metivier F, Pannier B, Adda H: Arterial media calcification in end-stage renal disease: Impact on all-cause and cardiovascular mortality. *Nephrol Dial Transplant* 18: 1731–1740, 2003
  7. Moe SM, Chen NX: Pathophysiology of vascular calcification in chronic kidney disease. *Circ Res* 95: 560–567, 2004
  8. El-Abbadi M, Giachelli CM: Mechanisms of vascular calcification. *Adv Chronic Kidney Dis* 14: 54–66, 2007
  9. Moe SM: Vascular calcification and renal osteodystrophy relationship in chronic kidney disease. *Eur J Clin Invest* 36[Suppl 2]: 51–62, 2006
  10. Braun J, Oldendorf M, Moshage W, Heidler R, Zeitler E, Luft FC: Electron beam computed tomography in the evaluation of cardiac calcification in chronic dialysis patients. *Am J Kidney Dis* 27: 394–401, 1996
  11. Wang AY, Wang M, Woo J, Lam CW, Li PK, Lui SF, Sanderson JE: Cardiac valve calcification as an important predictor for all-cause mortality and cardiovascular mortality in long-term peritoneal dialysis patients: A prospective study. *J Am Soc Nephrol* 14: 159–168, 2003
  12. Bellasi A, Ferramosca E, Muntner P, Ratti C, Wildman RP, Block GA, Raggi P: Correlation of simple imaging tests and coronary artery calcium measured by computed tomography in hemodialysis patients. *Kidney Int* 70: 1623–1628, 2006
  13. Murshed M, Harmey D, Millan JL, McKee MD, Karsenty G: Unique coexpression in osteoblasts of broadly expressed genes accounts for the spatial restriction of ECM mineralization to bone. *Genes Dev* 19: 1093–1104, 2005
  14. Reynolds JL, Joannides AJ, Skepper JN, McNair R, Schurgers LJ, Proudfoot D, Jahnen-Dechent W, Weissberg PL, Shanahan CM: Human vascular smooth muscle cells undergo vesicle-mediated calcification in response to changes in extracellular calcium and phosphate concentrations: A potential mechanism for accelerated vascular calcification in ESRD. *J Am Soc Nephrol* 15: 2857–2867, 2004
  15. O'Neill WC: The fallacy of the calcium-phosphorus product. *Kidney Int* 72: 792–796, 2007
  16. Ketteler M: Fetuin-A and extraosseous calcification in uremia. *Curr Opin Nephrol Hypertens* 14: 337–342, 2005