

# ANCA Disease: Where Is This Field Heading?

Ronald J. Falk\* and J. Charles Jennette†

\*University of North Carolina Kidney Center and †Pathology and Laboratory Medicine, University of North Carolina, Chapel Hill, Chapel Hill, North Carolina

## ABSTRACT

ANCA disease remains a subject of great experimental and clinical interest. The subcategories of names and descriptions for this collection of vasculitides and necrotizing glomerulonephritides is still a subject of some debate. The various forms of ANCA disease share some characteristics, and similar therapies are often recommended for overlapping categories of disease. The immunopathogenic effects of myeloperoxidase and proteinase 3 antibodies are well established, and good mechanisms for initiation of disease are starting to emerge, particularly the role of autoantigen complementarity. Here we examine these various topics and discuss an approach to treatment.

*J Am Soc Nephrol* 21: 745–752, 2010. doi: 10.1681/ASN.2009121238

ANCA are associated with pauci-immune necrotizing crescentic glomerulonephritis and small vessel vasculitis.<sup>1</sup> Since their discovery in 1982,<sup>2</sup> much has been learned about these autoantibodies, their target antigens, and association with a spectrum of clinicopathologic syndromes such as systemic vasculitis, respiratory tract disease, and necrotizing glomerulonephritis. Disease descriptions include Wegener granulomatosis, microscopic polyangiitis, Churg-Strauss syndrome, and renal-limited pauci-immune necrotizing and crescentic glomerulonephritis.

There have been substantial advances in the basic understanding and treatment of ANCA diseases in the past 20 years. In the 1980s and early 1990s, questions focused on ANCA diseases, the target autoantigens for ANCA, and whether ANCA participate in the pathogenesis of these diseases. Myeloperoxidase (MPO) and proteinase 3 (PR3) were soon discovered as major antigenic targets for ANCA in neutrophils and monocytes.<sup>1,3</sup> In the 1990s, *in vitro* observations suggested that ANCA participate in the pathogenesis of vascular inflamma-

tion.<sup>4–9</sup> The controversy over whether MPO-ANCA causes necrotizing glomerulonephritis and small vessel vasculitis dissipated with the development of convincing animal models.<sup>10–13</sup> The pathogenic potential of ANCA is supported by observations in patients, multiple levels of *in vitro* experimental evidence, and animal models, all confirming that antibodies to MPO cause glomerulonephritis and small vessel vasculitis in mice and rats.<sup>10,12–15</sup> Abundant *in vitro* evidence demonstrates that PR3-ANCA also cause leukocyte activation and endothelial cell destruction, although a convincing animal model has not been developed for PR3-ANCA glomerulonephritis or vasculitis.<sup>16</sup>

Clinical comparative efficacy and observational studies revealed effective treatment for induction and maintenance therapy, discussed later in this review.<sup>17–27</sup> The quantity and quality of these clinical studies are a consequence of the clarification of nomenclature provided by the Chapel Hill Consensus Conference<sup>28</sup> and the successes of collaborative efforts within the European Vasculitis Study Group (EUVAS),<sup>29</sup> the

European League Against Rheumatism (EULAR),<sup>30</sup> and the Vasculitis Clinical Research Consortium (VCRC).<sup>31,32</sup> Despite rapid and remarkable progress, further elucidation of this autoimmune disorder is needed to identify better treatment regimens that result in more effective, durable responses, if not cures, for these diseases.

## NOMENCLATURE: WHAT IS IN A NAME?

In 1994, the now routinely used Chapel Hill nomenclature<sup>28</sup> provided names and definitions for these vasculitides, including microscopic polyangiitis, Wegener granulomatosis, and Churg-Strauss syndrome. The Chapel Hill nomenclature was not intended to establish diagnostic criteria. To date, no widely adopted diagnostic criteria have been published to distinguish ANCA-associated disease from other vasculitides or to separate ANCA disease into clinicopathologic subcategories. There are a number of ongoing problems and controversies with nomenclature and diagnosis.

In practice, the clinical differentiation between Wegener granulomatosis and microscopic polyangiitis is difficult be-

Published online ahead of print. Publication date available at [www.jasn.org](http://www.jasn.org).

**Correspondence:** Dr. Ronald J. Falk, UNC Kidney Center, 7024 Burnett Womack/CB# 7155, University of North Carolina, Chapel Hill, NC 27599-7155. Phone: 919-966-2561; Fax: 919-966-4251; E-mail: [ronald\\_falk@med.unc.edu](mailto:ronald_falk@med.unc.edu); URL: <http://www.unckidneycenter.org>

Copyright © 2010 by the American Society of Nephrology

cause of similarities in their clinical and pathologic features, particularly the indistinguishable necrotizing glomerulonephritis. Where there are differences, as in the presence or absence of respiratory tract granulomatous inflammation, pathologic confirmation of granulomatous inflammation before implementing treatment is often unnecessary or unrewarding. Diagnosis of a patient's disease is not always based on rigorous, widely adopted criteria but rather is influenced by diverse personal and regional practices. For example, if one believes all patients with ear, nose, and throat disease have Wegener granulomatosis, then all such patients will carry that diagnosis, notwithstanding that some may not have or ever develop granulomatous inflammation. In reality, pathologic confirmation of a granulomatous process has become less important for patient treatment because of the similarity of therapy for microscopic polyangiitis and Wegener granulomatosis. The presence of a positive ANCA and pathologic confirmation of pauci-immune small vessel vasculitis or glomerulonephritis is sufficient to warrant immunosuppressive induction therapy, even if there is uncertainty about whether the patient should be diagnosed as having Wegener granulomatosis or microscopic polyangiitis.

In fact, the names microscopic polyangiitis and Wegener granulomatosis describe a clinicopathologic phenotype but are poor predictors of natural history of these two diseases compared with the predictive capacity of the ANCA serotype PR3-ANCA or MPO-ANCA.<sup>33,34</sup> PR3-ANCA, lung disease, and, to a lesser extent, upper respiratory tract disease predict the propensity for relapse better than a diagnosis of Wegener granulomatosis *versus* microscopic polyangiitis.

Awareness of Friedrich Wegener's Nazi connections has prompted efforts to remove his name from the eponym Wegener granulomatosis.<sup>35–39</sup> Although no definitive “smoking gun” has been discovered documenting Wegener's participation in Nazi war crimes, available records indicate he was an early member of the Nazi party and a member of the brownshirts (Strum Abteilung), the

paramilitary storm troopers of the early Nazi movement. As a pathologist in Lodz during World War II, his office was located a few blocks from the Lodz ghetto that was established to rid that city of Jews by deporting them to death or work camps. Reasonable evidence suggests that Wegener also served as a pathologist in the municipal health agency that issued reports on 50 to 100 autopsies a month on deaths in that municipality.

It is untenable to imagine that Wegener was unaware of Nazi atrocities. After 1945, Wegener was included on lists of war criminals, although the reasons are unknown. There is no evidence that he ever publicly renounced or apologized for his involvement with the Nazi party. In 2007, as a consequence of a careful review of the available data, the American College of Chest Physicians rescinded their Master Clinician Award given to Friedrich Wegener in 1989 and called for the removal of his eponymous distinction.<sup>38</sup> It is noteworthy that the most important advocacy organization for patients with Wegener granulomatosis, the Vasculitis Foundation, is thinking about dropping Wegener's name from their organization, in 2006 stating, “As patients and family members, we would prefer a different name for our disease” (Dianne Shaw, past president of the Vasculitis Society, personal communication, January 2008). It is time for the medical community studying vasculitis to agree on an alternative name for Wegener granulomatosis.

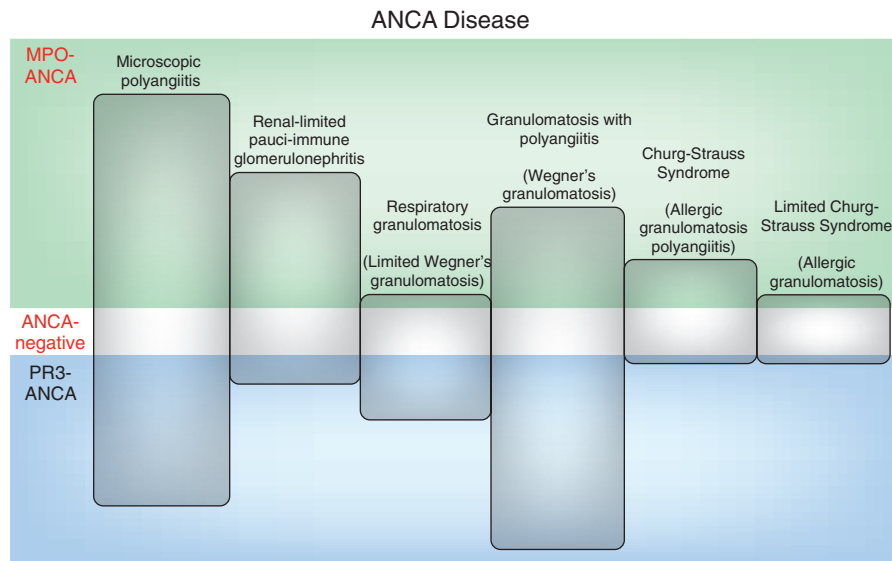
Wegener granulomatosis occurs as a systemic process with granulomatous inflammation, usually involving the respiratory tract, accompanied by necrotizing vasculitis affecting small- to medium-sized vessels including capillaries, venules, arterioles, and arteries.<sup>28</sup> Necrotizing glomerulonephritis is common, and Wegener granulomatosis also occurs in a localized or limited form in the upper and/or lower respiratory tract with no evidence of accompanying vasculitis. Thus, the granulomatosis and not the vasculitis is the *sine qua non* of this disease; therefore, a descriptive name for diagnosis should emphasize the granulomatosis and exclude the term vasculitis if

the name is to be used as an alternative designation for both the systemic and the limited expressions of this disease.

Wegener initially used the term “rhinogenic granulomatosis” for what is now called Wegener granulomatosis.<sup>40</sup> Churg and Strauss used the term “allergic granulomatosis” for what is now called Churg-Strauss syndrome.<sup>41</sup> Thus, the term granulomatosis has substantial historical precedence, which supports its retention in a noneponymous alternative for Wegener granulomatosis. One approach would be to use the term granulomatosis with polyangiitis (GPA) for disease with evidence of vasculitis (Figure 1, Table 1). The term respiratory granulomatosis could be used for disease limited to the respiratory tract but with no clinical or pathologic evidence of vasculitis.

The term ANCA-associated vasculitis (AAV) has been used to refer to the full spectrum of disease, including Wegener granulomatosis, microscopic polyangiitis, Churg-Strauss syndrome, and pauci-immune necrotizing glomerulonephritis. This is with the realization that some patients are ANCA-negative but have a clinically and pathologically identical disease to ANCA-positive patients. AAV is a problematic term for patients who have limited Wegener granulomatosis or limited Churg-Strauss syndrome, who have no evidence of vasculitis.

We propose that the most generic name for microscopic polyangiitis, Wegener granulomatosis, and Churg-Strauss syndrome could be ANCA disease, which is analogous to anti-glomerular basement membrane disease. If serologic data are known, then the designation could be PR3-ANCA disease, MPO-ANCA disease, or seronegative ANCA disease. Seronegative ANCA disease is conceptually analogous to seronegative systemic lupus erythematosus and seronegative rheumatoid arthritis. Clinicopathologic phenotypes could be designated ANCA granulomatosis (limited Wegener granulomatosis), ANCA granulomatosis with polyangiitis (GPA; Wegener granulomatosis), microscopic polyangiitis, or Churg-Strauss syndrome (Table 1). For example, GPA could be



**Figure 1.** A proposed nomenclature for ANCA disease.

further classified as PR3-ANCA GPA, MPO-ANCA GPA, or ANCA-negative GPA.

## ETIOLOGY AND PATHOGENESIS OF ANCA DISEASE

Although the close clinical association of ANCA with a distinctive type of small vessel inflammation raises the possibility of a pathogenic role for ANCA, the best support for this comes from animal models and *in vitro* experimental observations. Numerous *in vitro* studies reported by multiple research groups demonstrated that both MPO-ANCA and PR3-ANCA antibodies are capable of activating neutrophils and monocytes through both Fab'2 and Fc engagement, which initiates signal transduction pathways that are similar in neutrophils and monocytes (Figure 2).<sup>42–44</sup> Activation of these leukocytes results in adhesion to endothelial cells, causing endothelial damage in both cell culture and flow conditions.<sup>45–47</sup> Studies in mouse and rat models provide conclusive evidence that anti-MPO antibodies induce necrotizing and crescentic glomerulonephritis and systemic small vessel vasculitis.<sup>10–12</sup> Anti-MPO antibodies in the absence of functional T cells are capable of causing glomerulonephritis and vasculitis,<sup>10</sup> and the induction of this disease is dependent

on neutrophils.<sup>48</sup> It can be aggravated by a variety of cytokines, is dependent on activation of the alternative pathway of complement,<sup>49</sup> and is abrogated by inhibition of the alternative pathway and by anti-C5 receptor antibodies.<sup>49,50</sup> These studies provide a basis for exploring novel therapeutic strategies in human ANCA disease, such as inhibitors of alternative pathway activation, Fc receptors, or signaling pathways activated by ANCA.

Although multiple robust animal models of anti-MPO-induced disease have been developed, investigators have not been able to create a convincing animal model of anti-PR3-induced disease, despite the ample *in vitro* data showing that PR3-ANCA cause leukocyte activation. Why this has proved so difficult raises a number of possibilities, including that PR3-ANCA alone are not capable of inducing small vessel vasculitis and need some as-yet-unidentified synergistic factor.

## NEED FOR A "SECOND HIT"

More than one event is required for activation of neutrophils by ANCA (Figure 2). The autoantibodies must be present, but alterations in neutrophils also are required. In *in vitro* studies, neutrophils must be primed with TNF or other cyto-

kines to drive MPO and PR3 to the cell surface for interaction with ANCA.<sup>4</sup> If the autoantibody is the first hit, then a second hit requires autoantigen availability in the pathogenesis of ANCA disease. *In vivo*, an antecedent inflammatory process, such as a respiratory tract infection, could provide the necessary cytokines for increased autoantigen availability. A possible mechanism permitting ANCA to recognize antigens on the cell surface is suggested by studies from France and Germany showing that a genetically determined increase in membrane expression of PR3 could serve as the source of target antigen.<sup>51–55</sup> Another potential source for increased availability of autoantigens is aberrant transcription of neutrophil genes as a consequent loss of epigenetic silencing of MPO and PR3 genes.<sup>56,57</sup>

Patients with ANCA disease aberrantly express genes encoding neutrophil granules, including PR3 and MPO, and this expression profile correlates with disease activity.<sup>58</sup> Furthermore, despite that MPO and PR3 genes exist on different chromosomes, their respective levels of expression are upregulated during active disease and downregulated during remission.<sup>58</sup> Epigenetic changes as a result of loss of recruitment of the histone methylase PRC2 by Runx3 for both MPO and PR3 genes de-repress their transcription. Silencing is further diminished by

**Table 1.** ANCA-associated disease

Current Name	Alternative Name	Definition
Microscopic polyangiitis (MPA)	Microscopic polyangiitis (MPA)	Necrotizing vasculitis with few or no immune deposits affecting small vessels, (capillaries, venules, or arterioles); necrotizing arteritis involving small- and medium-sized arteries may be present; necrotizing glomerulonephritis is very common; pulmonary capillaritis often occurs
Wegener granulomatosis (WG)	Granulomatosis with polyangiitis (GPA)	Necrotizing granulomatous inflammation involving the respiratory tract accompanied by MPA-like lesions but without a history of asthma and blood eosinophilia
Limited WG	Respiratory granulomatosis (RG)	Necrotizing granulomatous inflammation involving the respiratory tract with no evidence of MPA-like lesions and no history of asthma and blood eosinophilia
Churg-Strauss syndrome (CSS)	Churg-Strauss syndrome or allergic granulomatosis with polyangiitis (AGPA)	Necrotizing granulomatous inflammation involving the respiratory tract accompanied by MPA-like lesions and a history of asthma and blood eosinophilia
Limited Churg-Strauss syndrome (CSS) without vasculitis or glomerulonephritis	Churg-Strauss syndrome or respiratory allergic granulomatosis (RAG)	Necrotizing granulomatous inflammation involving the respiratory tract with no evidence of MPA-like lesions and with a history of asthma and blood eosinophilia
Pauci-immune necrotizing and crescentic glomerulonephritis	Pauci-immune necrotizing and crescentic glomerulonephritis	Pauci-immune necrotizing and crescentic glomerulonephritis without systemic vasculitis

Each category can be ANCA-positive or ANCA-negative.

the induction of the histone demethylase Jumonji D3.<sup>57</sup>

## ORIGIN OF ANCA

ANCA cause disease, but what causes the appearance of ANCA? At least three different theories regarding the origin of the ANCA immune response have been proposed since 2004. The theory of autoantigen complementarity posits that a protein complementary (antisense) to the autoantigen (sense) initiates an immune response; and the anti-idiotypic counter-

response cross-reacts with the autoantigen (Figure 2).<sup>59</sup> This complementary protein could be derived endogenously by aberrant antisense transcription or exogenously from a pathogen using a complementary, antisense, mimicking protein that binds to and inhibits the antimicrobial properties of PR3 or MPO. The presence of PR3 anti-complementary specificity has been identified in both human antibodies and T cells. Moreover, this theory of autoantigen complementarity led to the discovery that protein complementary to the middle portion of PR3 is the endogenous

protein plasminogen.<sup>60</sup> Antibodies to plasminogen are detected in patients with ANCA disease, inhibit fibrinolysis, and associate with increased risk for thrombosis.

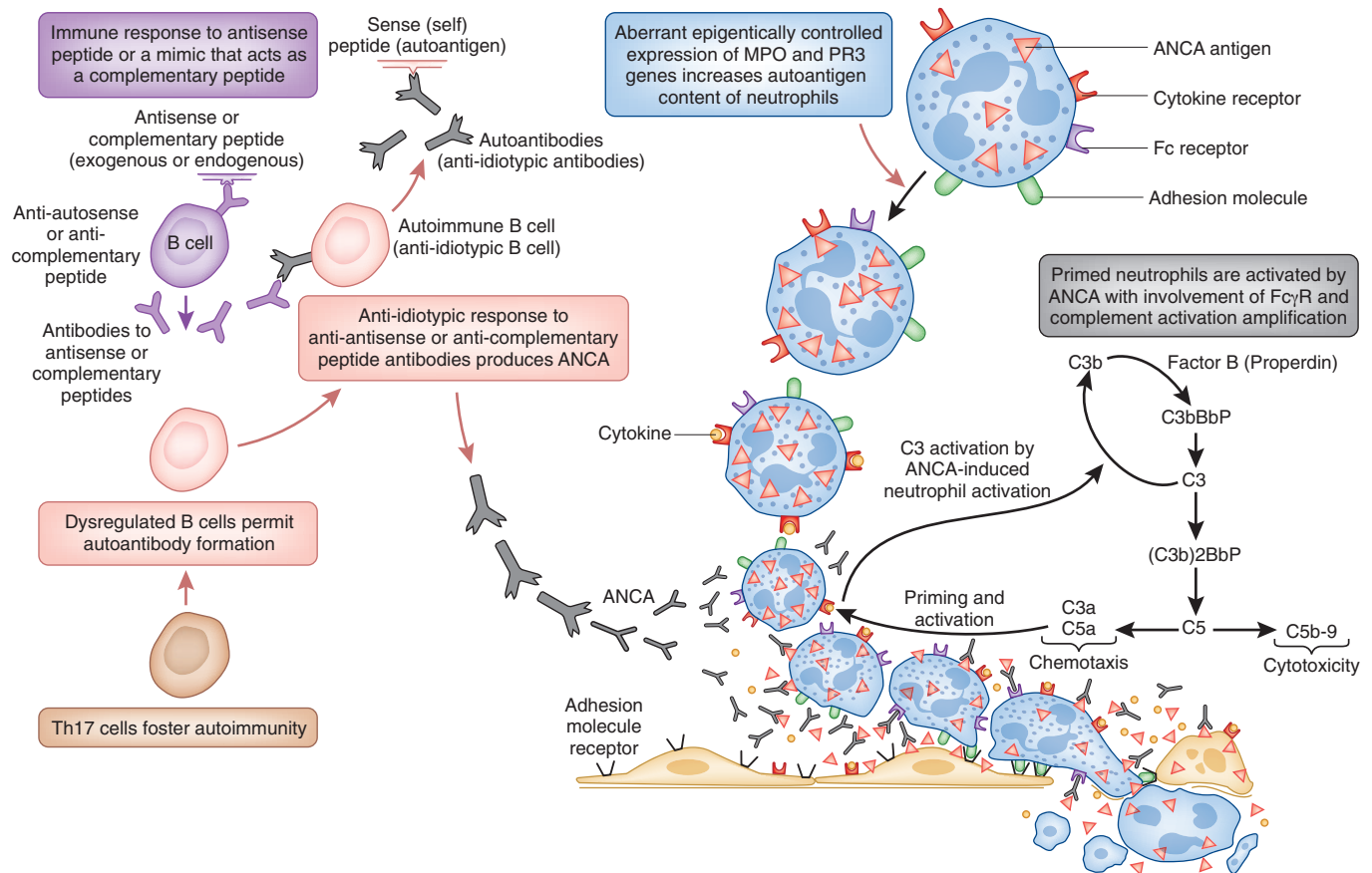
A second theory for the genesis of ANCA disease is based on the observation that patients with both MPO-ANCA and PR3-ANCA have antibodies to another neutrophil protein, lysosome-associated membrane protein 2 (LAMP2), that are capable of neutrophil activation and endothelial damage *in vitro*. LAMP2 has homology to a protein expressed by fimbriated bacteria (FimH). Antibodies to either FimH peptides or LAMP2 peptides are capable of inducing necrotizing and crescentic glomerulonephritis in rats. Hypothetically, anti-LAMP2 antibodies could result from molecular mimicry as a result infection with Gram-negative organisms making FimH.<sup>61</sup> Other research groups have not yet confirmed the association of LAMP2 antibodies with ANCA disease.

A third theory of causation is that neutrophils are surrounded by what are known as neutrophil nets that are a platform on which MPO and PR3 may be available to initiate an autoimmune response.<sup>62</sup>

## TREATMENT: MOVEMENT TOWARD CONSENSUS

Although previously diverse and controversial, therapy for ANCA disease has become more standardized today. Many studies now describe the results of randomized and controlled clinical trials addressing various aspects of ANCA disease management, including induction and maintenance therapies.<sup>17,19–23,26,27</sup> Induction of remission is aimed at quelling inflammation quickly. Pulses of methylprednisolone combined with immunosuppression effectively induce remission. Plasmapheresis is beneficial in patients with pulmonary hemorrhage<sup>63</sup> and in patients with severe kidney disease.<sup>20</sup> Entry serum creatinine and pulmonary hemorrhage are predictors of higher mortality.<sup>33</sup>

For many years, debate centered on



**Figure 2.** Immune mechanisms for ANCA. Depicted are hypothetical pathways for the immunogenesis of the ANCA autoimmune response (left) and the pathogenesis of ANCA vasculitis by ANCA (right). In the top left, we hypothesize the initial immunologic event in the induction of the ANCA autoimmune response is an immune response to an epitope with a structure that is complementary (antisense) to the autoantigen. This immunogen could be endogenous (e.g., an antisense transcript) or exogenous (e.g., an antisense mimic brought in by a microbe). The anti-idiotype immune response to this initial antibody produces anti-idiotype antibodies that cross-react with the autoantigen. We hypothesize the normal protection against autoimmunity is circumvented by dysregulated B cells and Th17 T cells (bottom left), allowing the autoimmune response to persist. We further hypothesize yet another event that fosters ANCA disease is the abnormal expression of genes in neutrophils that produce ANCA antigens (MPO and PR3; top right) and that this abnormality results from epigenetic dysregulation. These events set the stage for activation of neutrophils and resultant injury to vessels (bottom right), which begins with priming of neutrophils with  $\text{TNF-}\alpha$  or C5a, resulting in expression of target antigens (MPO or PR3) at the cell surface, where they are available to interact with ANCA. This results in neutrophil activation by both Fc receptor engagement and Fab'2 binding. Activated neutrophils release factors that engage the alternative complement pathway amplification loop with resultant chemotactic recruitment of neutrophils and additional neutrophil priming. Destructive factors released by activated neutrophils and generated by complement activation cause inflammatory injury to vessel walls (bottom left corner).

whether daily oral or pulse intravenous cyclophosphamide therapy results in the best short- or long-term outcomes.<sup>21,64,65</sup> In a meta-analysis of three randomized trials (totaling approximately 150 patients), intravenous pulse cyclophosphamide resulted in a significantly smaller cumulative dosage of cyclophosphamide, a nonsignificantly higher rate of remission, and a lower rate of leukopenia and serious adverse events, particularly infections.<sup>66</sup> These benefits were mitigated

by a higher rate of relapse in the pulse cyclophosphamide group that did not reach statistical significance. A EUVAS study has probably answered the debate.<sup>27</sup> A total of 149 patients who had newly diagnosed generalized AAV with renal involvement were randomly assigned to receive either pulse cyclophosphamide or daily oral cyclophosphamide. Cyclophosphamide was continued for 3 months beyond the time of remission, and patients were then switched to azathioprine. The two

treatment groups did not differ in time to remission or proportion of patients who achieved remission or had a relapse. Absolute cumulative cyclophosphamide dosage in the daily oral group was almost twice that of the pulse group. At last, the oral cyclophosphamide debate may be drawing to a close. Without a clear advantage of daily oral cyclophosphamide, we favor the pulse regimen as first-line induction therapy with a lower cumulative dosage and risks from severe leukopenia.

Whether cyclophosphamide can be further reduced or avoided completely by the use of rituximab was addressed in two randomized, controlled trials (soon to be published). In the Randomised Trial of Rituximab *versus* Cyclophosphamide for ANCA Associated Renal Vasculitis (RITUXVAS) trial, 44 patients with newly diagnosed ANCA vasculitis were randomly assigned 3:1 either to rituximab plus cyclophosphamide or to cyclophosphamide alone.<sup>24</sup> Rituximab for the treatment of Wegener granulomatosis and microscopic polyangiitis (Rituximab for ANCA-associated Vasculitis [RAVE] trial)<sup>67</sup> is a multicenter, double-blind, randomized, placebo-controlled trial of 197 patients to assess the noninferiority of rituximab plus corticosteroids *versus* cyclophosphamide plus corticosteroids in patients with new-onset and relapsing disease. In both trials, rituximab seems noninferior to cyclophosphamide. In the RITUXVAS, remissions were common (approximately 90%), whereas in the RAVE trial, the remission rate was much lower. In the RITUXVAS, severe adverse events were common, affecting 45% of patients in the rituximab group and 36% in the cyclophosphamide group alone. The 1-year mortality rate was elevated in both groups (18%). In the RAVE trial, the rate of adverse effects was similar. The evaluation of rituximab compared with cyclophosphamide awaits analysis of long-term outcomes, sustained remission, rate of relapses, and safety data. Importantly, rituximab may eventually become a useful tool worthy of therapeutic consideration, although it is unclear whether rituximab will be any safer than cyclophosphamide.

A variety of maintenance therapies have also been evaluated in several trials, including the CYClophosphamide or AZathioprine As a REMission therapy for vasculitis (CYCAZAREM) trial<sup>19</sup> (cyclophosphamide *versus* azathioprine), Wegener's Granulomatosis–Entretien (WEGENT) trial<sup>23</sup> (azathioprine *versus* methotrexate), Leflunomide *versus* Methotrexate in the Therapy of ANCA Vasculitis (LEM) study,<sup>25</sup> and Azathioprine *versus* Mycophenolate Mofetil in the therapy of ANCA Vasculitis (IM-

PROVE) study.<sup>26</sup> All of these approaches work, although azathioprine seems to be one of the best agents. Interestingly, the duration of glucocorticoid use remains controversial. Our own practice stops prednisone therapy in most patients by 16 weeks, whereas investigators in Europe continue low-dosage glucocorticoids for years.

Many drug combinations are effective in inducing and maintaining remission, but with all of these combinations, there should be concern about too much immunosuppression. In the CYCAZAREM trial,<sup>19</sup> eight patients died during induction and severe adverse events occurred in 10% of patients in the induction phase and in 10% of both study arms during the remission phase. In the Methylprednisolone *versus* Plasma Exchange as Additional Therapy for Severe ANCA Associated Glomerulonephritis (MEPEX) trial,<sup>20</sup> 25% of patients died in the first 3 months. In the Wegener's Granulomatosis Etanercept Trial (WGET),<sup>22,68</sup> the use of anti-TNF drugs resulted in significant cancers in a remarkable number of patients. In the RITUXVAS and the RAVE trial, adverse events also abound. Finding the most effective and least toxic regimens remains a major unmet need.

## LOOKING TO THE FUTURE

The biology of remission and relapse in ANCA disease is poorly understood. Clinical tools can predict disease relapse and remission, but they have limitations. The Birmingham Vasculitis Activity Score<sup>69</sup> is an efficient approach to defining disease remission at a given point in time but does not ensure that the patient will stay in remission. Multiple attempts have been made to predict propensity for relapse. Patients with PR3-ANCA; lung disease; and/or ear, nose, and throat disease have a higher likelihood of disease relapse.<sup>34</sup> A replication study demonstrated the predictive value of positive PR3-ANCA and lung disease, yet patients without these markers also experience relapse, although less frequently. We know so little about the biology of individuals who have a single-shot disease or experience only a single relapse

when compared with individuals who have repetitive relapses with or without remission maintenance therapy. We only partially understand the biology of remission and relapse in autoimmune disease and certainly not in ANCA disease. To alter fundamentally the clinical approach to maintenance therapy, we need to discover the mechanism underpinning relapse and what permits a long-term remission. A better understanding would directly benefit all therapeutic strategies. For example, patients who are likely to have long-term stable remission without therapy should not be exposed to needless maintenance immunosuppressive therapy. Biomarkers of remission and relapse would permit clinicians to withhold immunosuppressive therapy safely. Patients who are destined to relapse should have targeted therapy on the basis of the disease mechanisms causing their relapse.

## CONCLUSIONS

Since the first report of ANCA in 1982,<sup>2</sup> tremendous advances have been made in understanding the clinical, pathologic, and pathogenic nature of ANCA disease, and substantial improvements have been made in the treatment of ANCA disease; however, recently emerging insights into pathogenesis and the value of novel immunomodulatory therapies portend more important advances in the near future. We seem to be heading in the right direction.

## DISCLOSURES

None.

## REFERENCES

1. Falk RJ, Jennette JC: Anti-neutrophil cytoplasmic autoantibodies with specificity for myeloperoxidase in patients with systemic vasculitis and idiopathic necrotizing and crescentic glomerulonephritis. *N Engl J Med* 318: 1651–1657, 1988
2. Davies DJ, Moran JE, Niall JF, Ryan GB: Segmental necrotizing glomerulonephritis with antineutrophil antibody: Possible arbovirus aetiology? *BMJ (Clin Res Ed)* 285: 606, 1982

3. Goldschmeding R, van der Schoot CE, ten Bokkel HD, Hack CE, van den Ende ME, Kallenberg CG, de Borne AE: Wegener's granulomatosis autoantibodies identify a novel diisopropylfluorophosphate-binding protein in the lysosomes of normal human neutrophils. *J Clin Invest* 84: 1577–1587, 1989
4. Falk RJ, Terrell RS, Charles LA, Jennette JC: Anti-neutrophil cytoplasmic autoantibodies induce neutrophils to degranulate and produce oxygen radicals *in vitro*. *Proc Natl Acad Sci U S A* 87: 4115–4119, 1990
5. Jennette JC, Xiao H, Falk RJ: Pathogenesis of vascular inflammation by anti-neutrophil cytoplasmic antibodies. *J Am Soc Nephrol* 17: 1235–1242, 2006
6. Kallenberg CG, Zhao MH: Evolving concepts in pathogenesis and treatment of ANCA-associated systemic vasculitides. *Nephrology (Carlton)* 14: 1–2, 2009
7. Kain R, Firmin DA, Rees AJ: Pathogenesis of small vessel vasculitis associated with autoantibodies to neutrophil cytoplasmic antigens: New insights from animal models. *Curr Opin Rheumatol* 22: 15–20, 2010
8. Dhaygude A, Erdbruegger U, Haubitz M, Woywodt A: ANCA-associated vasculitis: Pathogenesis, novel markers of the disease and emerging therapies. *Minerva Urol Nefrol* 61: 411–437, 2009
9. Gomez-Puerta JA, Bosch X: Anti-neutrophil cytoplasmic antibody pathogenesis in small-vessel vasculitis: An update. *Am J Pathol* 175: 1790–1798, 2009
10. Xiao H, Heeringa P, Hu P, Liu Z, Zhao M, Aratani Y, Maeda N, Falk RJ, Jennette JC: Antineutrophil cytoplasmic autoantibodies specific for myeloperoxidase cause glomerulonephritis and vasculitis in mice. *J Clin Invest* 110: 955–963, 2002
11. Little MA, Smyth CL, Yadav R, Ambrose L, Cook HT, Nourshargh S, Pusey CD: Antineutrophil cytoplasm antibodies directed against myeloperoxidase augment leukocyte-microvascular interactions *in vivo*. *Blood* 106: 2050–2058, 2005
12. Little MA, Smyth L, Salama AD, Mukherjee S, Smith J, Haskard D, Nourshargh S, Cook HT, Pusey CD: Experimental autoimmune vasculitis: An animal model of anti-neutrophil cytoplasmic autoantibody-associated systemic vasculitis. *Am J Pathol* 174: 1212–1220, 2009
13. Pfister H, Ollert M, Froehlich LF, Quintanilla-Martinez L, Colby TV, Specks U, Jenne DE: Antineutrophil cytoplasmic autoantibodies against the murine homolog of proteinase 3 (Wegener autoantigen) are pathogenic *in vivo*. *Blood* 104: 1411–1418, 2004
14. Schlieben DJ, Korbet SM, Kimura RE, Schwartz MM, Lewis EJ: Pulmonary-renal syndrome in a newborn with placental transmission of ANCA. *Am J Kidney Dis* 45: 758–761, 2005
15. Savage CO, Harper L, Holland M: New findings in pathogenesis of antineutrophil cytoplasm antibody-associated vasculitis. *Curr Opin Rheumatol* 14: 15–22, 2002
16. Kallenberg CG: Antineutrophil cytoplasmic autoantibody-associated small-vessel vasculitis. *Curr Opin Rheumatol* 19: 17–24, 2007
17. de Groot K, Rasmussen N, Bacon PA, Tervaert JW, Feighery C, Gregorini G, Gross WL, Luqmani R, Jayne DR: Randomized trial of cyclophosphamide versus methotrexate for induction of remission in early systemic antineutrophil cytoplasmic antibody-associated vasculitis. *Arthritis Rheum* 52: 2461–2469, 2005
18. Langford CA, Talar-Williams C, Barron KS, Sneller MC: Use of a cyclophosphamide-induction methotrexate-maintenance regimen for the treatment of Wegener's granulomatosis: Extended follow-up and rate of relapse. *Am J Med* 114: 463–469, 2003
19. Jayne D, Rasmussen N, Andrassy K, Bacon P, Cohen Tervaert JW, Dadoniene J, Ekstrand A, Gaskin G, Gregorini G, de Groot K, Gross W, Hagen EC, Mirapeix E, Pettersson E, Siegert C, Sinico A, Tesar V, Westman K, Pusey C: A randomized trial of maintenance therapy for vasculitis associated with antineutrophil cytoplasmic autoantibodies. *N Engl J Med* 349: 36–44, 2003
20. Jayne DR, Gaskin G, Rasmussen N, Abramowicz D, Ferrario F, Guillevin L, Mirapeix E, Savage CO, Sinico RA, Stegeman CA, Westman KW, Van Der Woude FJ, de Lind van Wijngaarden RA, Pusey CD: Randomized trial of plasma exchange or high-dosage methylprednisolone as adjunctive therapy for severe renal vasculitis. *J Am Soc Nephrol* 18: 2180–2188, 2007
21. Falk RJ, Hogan S, Carey TS, Jennette JC: Clinical course of anti-neutrophil cytoplasmic autoantibody-associated glomerulonephritis and systemic vasculitis. The Glomerular Disease Collaborative Network. *Ann Intern Med* 113: 656–663, 1990
22. WGET Research Group: Etanercept plus standard therapy for Wegener's granulomatosis. *N Engl J Med* 352: 351–361, 2005
23. Pagnoux C, Mahr A, Hamidou MA, Boffa JJ, Ruivard M, Ducroix JP, Kyndt X, Lifermann F, Papo T, Lambert M, Le Noach J, Khellaf M, Merrien D, Puechal X, Vinzio S, Cohen P, Mouthon L, Cordier JF, Guillevin L: Azathioprine or methotrexate maintenance for ANCA-associated vasculitis. *N Engl J Med* 359: 2790–2803, 2008
24. Jones R, Walsh M, Jayne D, European Vasculitis Study Group: Randomised trial of rituximab versus cyclophosphamide for ANCA-associated renal vasculitis: RITUXVAS [Abstract]. *J Am Soc Nephrol* 19: 61A, 2008
25. Metzler C, Miehle N, Manger K, Iking-Konert C, de Groot K, Hellmich B, Gross WL, Reinhold-Keller E: Elevated relapse rate under oral methotrexate versus leflunomide for maintenance of remission in Wegener's granulomatosis. *Rheumatology (Oxford)* 46: 1087–1091, 2007
26. Hiemstra T, Walsh M, de Groot K, Hauser T, Mahr A, Pagnoux C, Harper L, Savage C, Tesar V, Neumann I, Wit EJ, Schmitt W, Jayne D: Randomized trial of mycophenolate mofetil vs. azathioprine for maintenance therapy in ANCA-associated vasculitis (IMPROVE). *APMIS* 117: 77–78, 2009
27. de Groot K, Harper L, Jayne DR, Flores Suarez LF, Gregorini G, Gross WL, Luqmani R, Pusey CD, Rasmussen N, Sinico RA, Tesar V, Vanhille P, Westman K, Savage CO: Pulse versus daily oral cyclophosphamide for induction of remission in antineutrophil cytoplasmic antibody-associated vasculitis: A randomized trial. *Ann Intern Med* 150: 670–680, 2009
28. Jennette JC, Falk RJ, Andrassy K, Bacon PA, Churg J, Gross WL, Hagen EC, Hoffman GS, Hunder GG, Kallenberg CG: Nomenclature of systemic vasculitides: Proposal of an international consensus conference. *Arthritis Rheum* 37: 187–192, 1994
29. Jayne DR, Rasmussen N: Treatment of antineutrophil cytoplasm autoantibody-associated systemic vasculitis: initiatives of the European Community Systemic Vasculitis Clinical Trials Study Group. *Mayo Clin Proc* 72: 737–747, 1997
30. Mukhtyar C, Flossmann O, Hellmich B, Bacon PA, Cid MC, Cohen Tervaert JW, Gross WL, Guillevin L, Jayne DR, Mahr A, Merkel PA, Raspe H, Scott DG, Witter J, Yazici H, Luqmani RA, European Vasculitis Study Group (EUVAS): Outcomes from studies of antineutrophil cytoplasm antibody associated vasculitis: A systematic review by the European League Against Rheumatism Systemic Vasculitis Task Force. *Ann Rheum Dis* 67: 1004–1010, 2008
31. Seo P, Jayne D, Luqmani R, Merkel PA: Assessment of damage in vasculitis: Expert ratings of damage. *Rheumatology (Oxford)* 48: 823–827, 2009
32. Merkel PA, Cuthbertson DD, Hellmich B, Hoffman GS, Jayne DR, Kallenberg CG, Krischer JP, Luqmani R, Mahr AD, Matteson EL, Specks U, Stone JH: Comparison of disease activity measures for anti-neutrophil cytoplasmic autoantibody (ANCA)-associated vasculitis. *Ann Rheum Dis* 68: 103–106, 2009
33. Hogan SL, Falk RJ, Chin H, Cai J, Jennette CE, Jennette JC, Nachman PH: Predictors of relapse and treatment resistance in antineutrophil cytoplasmic antibody-associated small-vessel vasculitis. *Ann Intern Med* 143: 621–631, 2005
34. Pagnoux C, Hogan SL, Chin H, Jennette JC, Falk RJ, Guillevin L, Nachman PH: Predictors of treatment resistance and relapse in antineutrophil cytoplasmic antibody-associated small-vessel vasculitis: Comparison of two independent cohorts. *Arthritis Rheum* 58: 2908–2918, 2008

35. Woywodt A, Haubitz M, Haller H, Matteson EL: Wegener's granulomatosis. *Lancet* 367: 1362–1366, 2006
36. Woywodt A, Matteson EL: Wegener's granulomatosis: Probing the untold past of the man behind the eponym. *Rheumatology (Oxford)* 45: 1303–1306, 2006
37. Rosen MJ: Dr. Friedrich Wegener, the ACCP, and history. *Chest* 132: 739–741, 2007
38. Rosen MJ: Dr. Friedrich Wegener and the ACCP, revisited. *Chest* 132: 1723–1724, 2007
39. Savel RH, Goldstein EB, Savel I, Savel H: Time does not heal all wounds: Medical luminaries, national socialism, and the American College of Chest Physicians. *Chest* 132: 2064–2065, 2007
40. Wegener F: About a strange rhinogenous granulomatosis including special participation of the arterial system and the kidneys [in German]. *Beitr Pathol Anat* 102: 36–68, 1939
41. Churg J, Strauss L: Allergic granulomatosis, allergic angiitis and periarteritis nodosa. *Am J Pathol* 27: 277–301, 1951
42. Franssen CF, Huitema MG, Muller Kobold AC, Oost-Kort WW, Limburg PC, Tiebosch A, Stegeman CA, Kallenberg CG, Tervaert JW: *In vitro* neutrophil activation by antibodies to proteinase 3 and myeloperoxidase from patients with crescentic glomerulonephritis. *J Am Soc Nephrol* 10: 1506–1515, 1999
43. Kettritz R, Jennette JC, Falk RJ: Crosslinking of ANCA-antigens stimulates superoxide release by human neutrophils. *J Am Soc Nephrol* 8: 386–394, 1997
44. Muller Kobold AC, van der Geld YM, Limburg PC, Tervaert JW, Kallenberg CG: Pathophysiology of ANCA-associated glomerulonephritis. *Nephrol Dial Transplant* 14: 1366–1375, 1999
45. Ewert BH, Jennette JC, Falk RJ: Anti-myeloperoxidase antibodies stimulate neutrophils to damage human endothelial cells. *Kidney Int* 41: 375–383, 1992
46. Savage CO, Pottinger BE, Gaskin G, Pusey CD, Pearson JD: Autoantibodies developing to myeloperoxidase and proteinase 3 in systemic vasculitis stimulate neutrophil cytotoxicity toward cultured endothelial cells. *Am J Pathol* 141: 335–342, 1992
47. Savage CO: Vascular biology and vasculitis. *APMIS Suppl* 37–40, 2009
48. Xiao H, Heering P, Hu P, Liu Z, Falk RJ, Jennette JC: A major role for neutrophils in the induction of necrotizing and crescentic glomerulonephritis by anti-myeloperoxidase IgG in mice. *Kidney Blood Press Res* 26: 255, 2003
49. Xiao H, Schreiber A, Heeringa P, Falk RJ, Jennette JC: Alternative complement pathway in the pathogenesis of disease mediated by anti-neutrophil cytoplasmic autoantibodies. *Am J Pathol* 170: 52–64, 2007
50. Huugen D, van Esch A, Xiao H, Peutz-Kootstra CJ, Buurman WA, Tervaert JW, Jennette JC, Heeringa P: Inhibition of complement factor C5 protects against anti-myeloperoxidase antibody-mediated glomerulonephritis in mice. *Kidney Int* 71: 646–654, 2007
51. Halbwegs-Mecarelli L, Bessou G, Lesavre P, Lopez S, Witko-Sarsat V: Bimodal distribution of proteinase 3 (PR3) surface expression reflects a constitutive heterogeneity in the polymorphonuclear neutrophil pool. *FEBS Lett* 374: 29–33, 1995
52. Hellmich B, Csernok E, Trabandt A, Gross WL, Ernst M: Granulocyte-macrophage colony-stimulating factor (GM-CSF) but not granulocyte colony-stimulating factor (G-CSF) induces plasma membrane expression of proteinase 3 (PR3) on neutrophils *in vitro*. *Clin Exp Immunol* 120: 392–398, 2000
53. Schreiber A, Busjahn A, Luft FC, Kettritz R: Membrane expression of proteinase 3 is genetically determined. *J Am Soc Nephrol* 14: 68–75, 2003
54. Hu N, Westra J, Huitema MG, Bijl M, Brouwer E, Stegeman CA, Heeringa P, Limburg PC, Kallenberg CG: Coexpression of CD177 and membrane proteinase 3 on neutrophils in antineutrophil cytoplasmic autoantibody-associated systemic vasculitis: Anti-proteinase 3-mediated neutrophil activation is independent of the role of CD177-expressing neutrophils. *Arthritis Rheum* 60: 1548–1557, 2009
55. Kallenberg CG: Pathogenesis of PR3-ANCA associated vasculitis. *J Autoimmun* 30: 29–36, 2008
56. Yang JJ, Ciavatta D, Magnuson T, Preston GA, Falk RJ: Histone H3K27 demethylase and methyltransferase activities contribute to the epigenetic silencing of proteinase 3 (PR3) and myeloperoxidase (MPO) in patients with ANCA disease. *J Am Soc Nephrol* 19: 2008
57. Preston GA, Ciavatta D, Yang JJ, Hewins P, Badhwar A, Jennette JC, Falk RJ: Normal gene silencing mechanisms in mature neutrophils are disrupted in ANCA vasculitis. *APMIS* 117: 122–123, 2009
58. Yang JJ, Pendergraft WF, Alcorta DA, Nachman PH, Hogan SL, Thomas RP, Sullivan P, Jennette JC, Falk RJ, Preston GA: Circumvention of normal constraints on granule protein gene expression in peripheral blood neutrophils and monocytes of patients with antineutrophil cytoplasmic autoantibody-associated glomerulonephritis. *J Am Soc Nephrol* 15: 2103–2114, 2004
59. Pendergraft WF, Preston GA, Shah RR, Tropsha A, Carter CW, Jennette JC, Falk RJ: Autoimmunity is triggered by cPR-3(105–201), a protein complementary to human autoantigen proteinase-3. *Nat Med* 10: 72–79, 2004
60. Bautz DJ, Preston GA, Lionaki S, Hewins P, Wolberg AS, Yang JJ, Hogan SL, Chin H, Moll S, Jennette JC, Falk RJ: Antibodies with dual reactivity to plasminogen and complementary PR3 in PR3-ANCA vasculitis. *J Am Soc Nephrol* 19: 2421–2429, 2008
61. Kain R, Exner M, Brandes R, Ziehermayr R, Cunningham D, Alderson CA, Davidovits A, Raab I, Jahn R, Ashour O, Spitzauer S, Sunder-Plassmann G, Fukuda M, Klemm P, Rees AJ, Kerjaschki D: Molecular mimicry in pauci-immune focal necrotizing glomerulonephritis. *Nat Med* 14: 1088–1096, 2008
62. Kessenbrock K, Krumbholz M, Schonermarck U, Back W, Gross WL, Werb Z, Grone HJ, Brinkmann V, Jenne DE: Netting neutrophils in autoimmune small-vessel vasculitis. *Nat Med* 15: 623–625, 2009
63. Klemmer PJ, Chalermkulrat W, Reif MS, Hogan SL, Henke DC, Falk RJ: Plasmapheresis therapy for diffuse alveolar hemorrhage in patients with small-vessel vasculitis. *Am J Kidney Dis* 42: 1149–1153, 2003
64. Hoffman GS, Leavitt RY, Fleisher TA, Minor JR, Fauci AS: Treatment of Wegener's granulomatosis with intermittent high-dose intravenous cyclophosphamide. *Am J Med* 89: 403–410, 1990
65. Guillevin L, Cordier JF, Lhote F, Cohen P, Jarrousse B, Royer I, Lesavre P, Jacquot C, Bindi P, Bielefeld P, Desson JF, Detree F, Dubois A, Hachulla E, Hoen B, Jacomy D, Seigneuric C, Lauque D, Stern M, Longy-Boursier M: A prospective, multicenter, randomized trial comparing steroids and pulse cyclophosphamide versus steroids and oral cyclophosphamide in the treatment of generalized Wegener's granulomatosis. *Arthritis Rheum* 40: 2187–2198, 1997
66. de Groot K, Adu D, Savage CO: The value of pulse cyclophosphamide in ANCA-associated vasculitis: Meta-analysis and critical review. *Nephrol Dial Transplant* 16: 2018–2027, 2001
67. Stone JH, Merkel PA, Seo P, Spiera R, Langford CA, Hoffman GS, Kallenberg CGM, St. Clair E, William Fessler BJ, T'chao N, Ding L, Webber LV, Ikle D, Weitzkamp D, Wu W, Brunetta P, Seismundo L, Fervenza FC, Keogh KA, Kissin EY, Mieras KS, Monach PA, Peikert T, Stegeman C, Ytterberg SR, Specks U, The RAVE-ITN Research Group: Rituximab versus cyclophosphamide for induction of remission in ANCA-associated vasculitis: a randomized controlled trial (RAVE) [abstract 550]. *Arthritis Rheum* 60(Suppl): S204, 2009
68. Stone JH, Holbrook JT, Marriott MA, Tibbs AK, Seismundo LP, Min YI, Specks U, Merkel PA, Spiera R, Davis JC, St. Clair EW, McCune WJ, Ytterberg SR, Allen NB, Hoffman GS: Solid malignancies among patients in the Wegener's Granulomatosis Etanercept Trial. *Arthritis Rheum* 54: 1608–1618, 2006
69. Luqmani RA, Bacon PA, Moots RJ, Janssen BA, Pall A, Emery P, Savage C, Adu D: Birmingham Vasculitis Activity Score (BVAS) in systemic necrotizing vasculitis. *QJM* 87: 671–678, 1994