

# Tubular Lesions Predict Renal Outcome in Antineutrophil Cytoplasmic Antibody–Associated Glomerulonephritis after Rituximab Therapy

Annelies E. Berden,\* Rachel B. Jones,<sup>†</sup> Dianhdra D. Erasmus,\* Michael Walsh,<sup>‡</sup> Laure-Hélène Noël,<sup>§</sup> Franco Ferrario,<sup>||</sup> Rüdiger Waldherr,\*\* Jan A. Bruijn,\* David R. Jayne,<sup>†</sup> and Ingeborg M. Bajema,\* on behalf of the European Vasculitis Society

\*Department of Pathology, Leiden University Medical Center, Leiden, Netherlands; <sup>†</sup>Renal Unit, Addenbrooke's Hospital, Cambridge, United Kingdom; <sup>‡</sup>Department of Medicine, McMaster University, Hamilton, Ontario, Canada; <sup>§</sup>INSERM U845, Paris V University, Hôpital Necker, Paris, France; <sup>||</sup>Nephropathology Center, San Gerardo Hospital, Monza, Italy; <sup>¶</sup>Milan Bicocca University, Milan, Italy; and <sup>\*\*</sup>Department of Pathology, University of Heidelberg, Heidelberg, Germany

## ABSTRACT

Histopathological features in renal biopsies of patients with antineutrophil cytoplasmic antibody–associated vasculitis have predictive value for renal outcome in patients who receive standard treatment with cyclophosphamide and corticosteroids; however, whether the same holds true for rituximab-treated patients is unknown. We describe associations between renal histopathology and outcomes among patients treated with a rituximab-based regimen in the Randomized Trial of Rituximab versus Cyclophosphamide in ANCA-Associated Vasculitis trial. Two pathologists, blinded to clinical data, reviewed biopsies from 30 patients according to a standardized protocol that included assessment of T cell, B cell, and plasma cell infiltration, as well as scoring for tubulitis, interstitial inflammation, and glomerulitis. We did not observe associations between immunohistology scores and age, sex, estimated GFR at entry, or requirement for dialysis. However, tubulointerstitial inflammation was more severe among patients who had a positive test for the myeloperoxidase antineutrophil cytoplasmic antibody. In a multiple linear regression model, both CD3<sup>+</sup> T cell tubulitis and tubular atrophy independently associated with estimated GFR at 12 months. Tubular atrophy remained an independent predictor at 24 months ( $P < 0.01$ ). These results suggest that in addition to anti-B cell therapy, therapy directed at T cells may improve renal outcomes in antineutrophil cytoplasmic antibody–associated vasculitis.

*J Am Soc Nephrol* 23: 313–321, 2012. doi: 10.1681/ASN.2011040330

Established treatment regimens for systemic antineutrophil cytoplasmic antibody (ANCA)–associated vasculitis (AAV) and GN, consisting of cyclophosphamide and high-dose glucocorticoids, target both T and B cells. Standard treatment is associated with serious adverse events and the accumulation of therapy-related adverse events is an important cause of early mortality.<sup>1,2</sup> Therefore, ongoing studies involve the search for treatments that improve rates of sustained remission while minimizing adverse events.

Several small studies of off-label treatment with rituximab, an anti-CD20 mAb, suggest that it induces remission in patients with systemic AAV refractory to standard therapy.<sup>3–11</sup> A multicenter

study of 65 patients with refractory AAV demonstrated peripheral B cell depletion in all patients after a first course of rituximab, and complete remission was achieved in 75% ( $n=49$ ) of patients.<sup>12</sup> Of the 49 patients who experienced initial complete

Received April 1, 2011. Accepted September 7, 2011.

Published online ahead of print. Publication date available at [www.jasn.org](http://www.jasn.org).

**Correspondence:** Dr. Annelies E. Berden, Department of Pathology L1-Q (P0-107), Leiden University Medical Center, PO Box 9600, 2300 RC Leiden, Netherlands. Email: [A.E.Berden@lumc.nl](mailto:A.E.Berden@lumc.nl)

Copyright © 2012 by the American Society of Nephrology

remission, 29 patients relapsed (57%) with a median time to relapse of approximately 11.5 months.<sup>12</sup> Combined results from the aforementioned studies demonstrate that remission rates of 80%–90% are achieved with rituximab treatment among patients with refractory AAV. After these promising results in refractory disease, two international, multicenter, randomized, controlled trials (Randomized Trial of Rituximab versus Cyclophosphamide in ANCA-Associated Vasculitis [RITUXVAS] and Rituximab in ANCA-Associated Vasculitis Trial [RAVE]) were launched to investigate the efficacy of rituximab in the induction phase of AAV treatment.

The RITUXVAS trial compared a rituximab-based regimen with a standard cyclophosphamide/azathioprine regimen for the treatment of active, generalized AAV. All patients had renal involvement. Temporary use of two initial cyclophosphamide doses in the experimental rituximab-based trial limb was instigated to aid rapid disease control. The RITUXVAS trial investigated whether rituximab induced a higher rate of sustained remission compared with standard therapy, with a lower rate of severe adverse events and reduced cyclophosphamide exposure. Although sustained remission rates at 12 months were high in both treatment groups (76% in the rituximab group versus 82% in the control group), the rituximab-based regimen was not superior to standard intravenous cyclophosphamide therapy, nor was it associated with a reduction in early severe adverse events.<sup>13</sup> In the RAVE trial, patients were randomly assigned to receive rituximab or standard therapy with oral cyclophosphamide. The patients in the RAVE experimental group did not receive a single dose of cyclophosphamide. In agreement with the RITUXVAS study, the RAVE trial demonstrated that at 6 months of follow-up rituximab was not inferior to cyclophosphamide.<sup>14</sup>

These results indicate that rituximab might be a good substitute for cyclophosphamide as a form of induction therapy for AAV patients. However, because rituximab is a B cell–depleting agent, the question arises as to whether T cell–mediated lesions are as effectively treated with rituximab as with cyclophosphamide-based therapy. This study compares histopathological lesions of interest to renal outcome in 30 patients who took part in the experimental arm of the RITUXVAS trial. Specifically, renal T cell, B cell, and plasma cell infiltration were assessed and related to renal outcome. We compared our results with the literature on histologic predictors of renal outcome in AAV patients treated with standard therapy.

**RESULTS**

**Patients**

Of the 33 patients who participated in the RITUXVAS trial and received a

rituximab-based regimen, 30 had a renal biopsy and were included in this study. For 28 patients, the amount of tissue in the paraffin block allowed collection of additional unstained slides for immunohistochemical stainings. The mean number of glomeruli per biopsy was 13 (range, 2–55).

Nine patients received adjunctive plasmapheresis, and 21 received intravenous methylprednisolone. In all patients, biopsies were obtained before administration of rituximab, cyclophosphamide, or plasmapheresis. Biopsies were obtained before the start of steroid treatment in 17 patients and after the start of steroid treatment in nine patients. For the remaining four patients, the interval between biopsy and start of steroid treatment could not be determined.

The mean age at entry was 63.3 years (SD 16.8 years; range, 20–85 years). Fourteen patients were women and 16 were men. The mean ± SD baseline eGFR was 29.2±24.9 ml/min per 1.73 m<sup>2</sup>. Seven patients were receiving dialysis. Fifteen patients had a diagnosis of microscopic polyangiitis (MPA) or renal-limited vasculitis (RLV) and an equal number had a diagnosis of granulomatosis with polyangiitis (GPA, formerly Wegener’s granulomatosis).<sup>15–17</sup> The myeloperoxidase antineutrophil cytoplasmic antibody (MPO-ANCA) was detected in 13 patients, and the proteinase 3 antineutrophil cytoplasmic antibody (PR3-ANCA) was detected in 17 patients.

**Clinicopathological Correlations at Baseline**

As illustrated in Table 1, patients with higher percentages of normal glomeruli, not affected by the disease, presented with a relatively preserved renal function ( $r=0.54, P=0.002$ ). Patients with ≥50% normal glomeruli presented with a mean ± SD eGFR of 40.7±27.4 ml/min per 1.73 m<sup>2</sup>, and two of these patients were nevertheless receiving dialysis. Conversely, patients with <50% normal glomeruli presented with a mean ± SD eGFR of 22.6±21.4 ml/min per 1.73 m<sup>2</sup>

**Table 1.** Correlations of glomerular, tubulointerstitial, and vascular renal lesions with renal function at baseline and during follow-up

	MDRD at Entry		MDRD at 6 mo		MDRD at 12 mo		MDRD at 24 mo	
	<i>r</i>	<i>P</i>	<i>r</i>	<i>P</i>	<i>r</i>	<i>P</i>	<i>r</i>	<i>P</i>
Glomeruli								
normal	0.536	0.002	—	—	0.383	0.065	—	—
all crescents	−0.366	0.046	—	—	—	—	—	—
circumferential crescents	−0.353	0.056	—	—	—	—	—	—
cellular crescents	−0.339	0.067	—	—	—	—	—	—
fibrous crescents	—	—	—	—	−0.381	0.066	—	—
global sclerosis	—	—	—	—	−0.378	0.069	—	—
Tubulointerstitium								
interstitial infiltrate	neg	0.030	—	—	—	—	—	—
neutrophil infiltrate	neg	0.028	—	—	—	—	—	—
interstitial fibrosis	—	—	neg	0.049	neg	0.021	neg	0.023
tubular atrophy	—	—	neg	0.003	neg	0.002	neg	0.003
arteriosclerosis	—	—	—	—	neg	0.016	neg	0.031

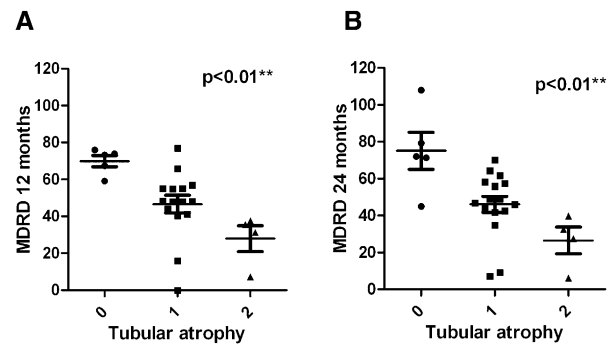
Dashes indicate  $P>0.10$ ; the values were omitted for table clarity. Neg, a negative correlation between the histologic parameter under investigation and renal function values.

and five of these patients were dialysis dependent. Patients with evidence of active GN, as characterized by the percentage of crescentic glomeruli, had a comparatively reduced baseline renal function ( $r = -0.37$ ,  $P = 0.046$ ). Patients whose biopsies contained  $\geq 50\%$  glomeruli with crescents presented with a mean  $\pm$  SD eGFR of  $18.3 \pm 18.3$  ml/min per  $1.73$  m<sup>2</sup>, and eGFR was  $37.5 \pm 26.6$  ml/min per  $1.73$  m<sup>2</sup> for those patients whose biopsies demonstrated  $< 50\%$  crescentic glomeruli. A comparatively reduced baseline renal function was particularly seen in patients whose biopsies showed higher percentages of cellular and/or circumferential crescents; however, this did not reach statistical significance. Interstitial infiltrates and extensive neutrophil infiltrates in the diagnostic biopsy correlated with an impaired renal function at presentation as well.

Apart from investigating associations between single histologic parameters and baseline renal function, biopsies were classified according to the recently developed classification schema for ANCA-associated GN.<sup>18</sup> We classified 26 of 30 biopsies containing  $\geq 5$  whole glomeruli. Of these biopsies, 10 were classified as focal, 10 as crescentic, and six as mixed. In the focal group, one biopsy contained 50% normal glomeruli and 50% cellular crescents (10 whole glomeruli, five normal glomeruli, five cellular crescents). In the mixed category ( $n = 6$ ), on average, 31% of glomeruli in the biopsy were normal, 24% showed cellular crescents, and 17% showed global glomerulosclerosis. These results indicate that these biopsies contained relatively few glomeruli with chronic damage. There was a significant association between renal biopsy class and baseline eGFR ( $P = 0.014$ ). Patients whose biopsies were classified as focal or mixed presented with better renal function (mean  $\pm$  SD eGFR focal class  $43.6 \pm 27.1$  ml/min per  $1.73$  m<sup>2</sup>; mixed class  $44.2 \pm 20.6$  ml/min per  $1.73$  m<sup>2</sup>) than patients whose biopsies were classified as crescentic ( $13.9 \pm 14.4$  ml/min per  $1.73$  m<sup>2</sup>).

### Histopathology and Outcome: Univariate Analyses

Whereas active glomerular and interstitial lesions correlated with reductions in renal function at the time of biopsy, chronic glomerular and interstitial lesions present in the diagnostic biopsy demonstrated an effect during follow-up. Patients with a higher proportion of glomeruli with fibrous crescents and/or globally sclerosed glomeruli tended to have a relatively impaired renal function after 1 year of follow-up. A high amount of tubular atrophy and the presence of diffuse interstitial fibrosis were associated with impaired renal function during follow-up as well (Figure 1A and B). Comparing these findings to the literature on histologic predictors of renal outcome in patients receiving standard therapy, it is evident that global glomerulosclerosis<sup>20,21</sup> and tubular atrophy<sup>20–22</sup> have consistently been shown to have predictive value for renal outcome. There were three patients who did not have evidence of arteriosclerosis on renal biopsy examination, and these patients had favorable renal outcomes compared with the majority of patients who presented with arteriosclerotic lesions (Table 1).



**Figure 1.** Tubular atrophy and renal function. Renal function at 1-year (A) and 2-year (B) follow-up is depicted according to the degree of tubular atrophy, as scored using a previously standardized protocol (Bajema et al.<sup>19</sup>). Data are presented as mean  $\pm$  SEM.

No relationship between glomerular or tubulointerstitial lesions and time to clinical remission was demonstrated in this cohort (data not shown). However, time to clinical remission was significantly longer for patients with evidence of arteriosclerosis than for patients without arteriosclerosis ( $P = 0.021$ ).

Renal function data at 1- and 2-year follow-up were available for 22 of 26 patients whose biopsies could be classified according to the recently devised schema; however, no significant association between biopsy class and renal function during follow-up could be demonstrated.

### Immunostainings

Tubulitis on CD3, CD79a, and CD20 scores was generally mild, with only a few immune cells per tubular cross-section (Table 2). Tubulitis on CD138 staining could not be evaluated due to CD138 staining of proximal tubular epithelium. On CD3 staining, almost half of the biopsies classified as t1 and the remainder classified as t0. In the focal class biopsies, only one of nine stained biopsies showed CD3+ T cell tubulitis. In the crescentic and mixed class biopsies, six of eight and four of six stained biopsies, respectively, showed this lesion. Regarding CD79a and CD20 staining, approximately 20% of biopsies classified as t1 and all other biopsies classified as t0.

Interstitial infiltrate scores were occasionally high for all evaluated cell types. Severe i3 interstitial inflammation was present in approximately 10% of biopsies upon examining cell counts for CD3+ T cells, CD79a+ and/or CD20+ B cells, and CD138+ plasma. Because CD20 staining is a parameter of particular interest in these rituximab-treated patients, it is of interest that the renal biopsies of six patients (approximately 21%) did not show any interstitial CD20+ B cells. However, CD20+ cells were present in the majority of biopsies (Table 2).

Glomerulitis was scarcely present; most biopsies were classified as g0. Regarding CD3+ T cell staining, five biopsies showed a class 1 glomerulitis and one biopsy was classified as g2. No intraglomerular CD3+ T cells were present in the other biopsies. Regarding CD79a, CD20, and CD138 stains, approximately 10%–15% of biopsies were classified as g1, and the rest were g0.

**Table 2.** Immunohistology data scored after the Banff 97 score for renal allograft nephropathy

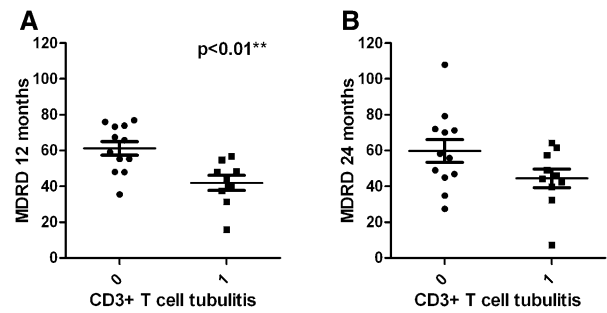
	CD3	CD20	CD79a	CD138
Tubulitis, n (%)				
0	15 (58)	23 (82)	21 (75)	—
1	11 (42)	5 (18)	7 (25)	—
total	26 (100)	28 (100)	28 (100)	—
missing	4	2	2	—
Interstitial inflammation, n (%)				
0	10 (39)	6 (21)	6 (21)	9 (32)
1	7 (27)	15 (54)	16 (57)	11 (39)
2	6 (23)	5 (18)	3 (11)	5 (18)
3	3 (12)	2 (7)	3 (11)	3 (11)
total	26 (100)	28 (100)	28 (100)	28 (100)
missing	4	2	2	2
Glomerulitis, n (%)				
0	17 (74)	20 (83)	23 (85)	24 (92)
1	5 (22)	4 (17)	4 (15)	2 (8)
2	1 (4)	0 (0)	0 (0)	0 (0)
total	23 (100)	24 (100)	27 (100)	26 (100)
missing	7	6	3	4

Tubulitis: 0, no mononuclear cells in tubules; t1, foci with 1–4 cells/tubular cross-section (or 10 tubular cells). Interstitial inflammation: 0, no or trivial interstitial inflammation (<10% of unscarred parenchyma); i1, 10%–25% of parenchyma inflamed; i2, 26%–50% of parenchyma inflamed; i3, >50% of parenchyma inflamed. Glomerulitis: 0, no glomerulitis; g1, glomerulitis in <25% of glomeruli; g2, segmental or global glomerulitis in 25%–75% of glomeruli (Racusen et al.<sup>23</sup>).

There was no difference in Banff 97 scores according to patient sex, age, diagnosis, time to remission, dialysis at entry, and renal function at entry, demonstrating that these histologic parameters are unique and not simply markers of age or renal function. Patients who had a positive test for MPO-ANCA demonstrated more extensive tubulointerstitial inflammation upon renal biopsy examination. Specifically, these patients had higher CD20 tubulitis scores, as well as higher CD3 and CD138 interstitial inflammation scores, than those patients who had a positive test for PR3-ANCA.

Intraepithelial CD3+ T cells in the renal biopsy correlated to an increased serum creatinine and an impaired eGFR, as estimated by the Modification of Diet in Renal Disease (MDRD) formula, at 6 months ( $P<0.05$ ) and 12 months ( $P<0.01$ ) but not at 24 months of follow-up ( $P=0.093$ ) (Figure 2A and B). The two patients who had intraglomerular CD20-positive B cells demonstrated a very impaired eGFR during follow-up at 6 ( $P<0.05$ ) and 12 months (eGFR [mean  $\pm$  SD, ml/min per 1.73 m<sup>2</sup>] intraglomerular B cells present  $26.74 \pm 15.31$ , intraglomerular B cells absent  $56.84 \pm 12.64$ ;  $P<0.05$ ). The same trend ( $P=0.083$ ) was demonstrated regarding intraglomerular CD20 positive B cells and eGFR at 24 months of follow-up.

Because the immunostainings could not be compared with the literature on histologic predictors of renal outcome, renal biopsy sections from the standard treatment group were also immunostained. There were no significant differences in immunostainings between the rituximab-treated group and the



**Figure 2.** T cell tubulitis and renal function. Renal function at 1-year (A) and 2-year (B) follow-up is depicted according to the degree of CD3+ T cell tubulitis, as scored using the Banff 97 score for renal allograft nephropathy (Racusen et al.<sup>23</sup>). Data are presented as mean  $\pm$  SEM.

standard treatment group. Furthermore, intraepithelial CD3+ T cells did not correlate with reductions in eGFR during follow-up in the standard treatment group.

### Independent Predictors for eGFR at 1- and 2-Year Follow-Up

Backward stepwise linear regression analysis was performed including clinical and histopathological candidate predictor variables for renal function at 1- and 2-year follow-up. Clinically, entry eGFR was strongly correlated to eGFR at 12 months ( $r=0.486$ ,  $P=0.016$ ) and there was a tendency for an effect of age ( $r=-0.364$ ,  $P=0.08$ ). Histologically, normal glomeruli, globally sclerosed glomeruli, and fibrous crescents were candidate predictors for eGFR at 12 months (all  $P<0.10$ ). Tubular atrophy and interstitial fibrosis were the most important interstitial parameters considering their univariate correlation to eGFR at follow-up, and CD3+ tubulitis was an important candidate predictor in regard to immunostaining (all  $P<0.05$ ).

Entering these candidate predictors in the backward stepwise linear regression model demonstrated that tubular atrophy (extensive tubular atrophy  $B=-27.2$ ; 95% confidence interval [95% CI],  $-45.9$  to  $-8.5$ ;  $P=0.007$ ) and CD3+ T cell-tubulitis ( $B=-11.9$ ; 95% CI,  $-23.7$  to  $-0.2$ ;  $P=0.047$ ) were the most important independent predictors of eGFR at 12 months. Regarding renal function at 24 months, only tubular atrophy (small foci of tubular atrophy  $B=-26.0$ ; 95% CI,  $-44.0$  to  $-8.0$ ;  $P=0.007$ ; extensive tubular atrophy  $B=-41.9$ ; 95% CI,  $-67.1$  to  $-16.6$ ;  $P=0.003$ ) remained an independent predictor.

The adjusted  $R^2$  values for the models at 1- and 2-year follow-up were 0.53 and 0.36, respectively, indicating that these models incorporating baseline histologic parameters explain approximately 53% and 36% of the variation in renal function at 1- and 2-year follow-up. In comparison,  $R^2$  values for univariate linear regression analyses incorporating only baseline renal function and investigating renal outcome were 0.25 and 0.23 at 1-year ( $B=0.39$ ; 95% CI  $0.09-0.69$ ;  $P=0.014$ ) and 2-year follow-up ( $B=0.43$ ; 95% CI  $0.09-0.77$ ;  $P=0.017$ ),

respectively. These results indicate that baseline renal function alone predicts approximately 23%–25% of the variation in renal function at 1- and 2-year follow-up.

## DISCUSSION

Rapidly progressive GN is an important disease manifestation of AAV that accounts for substantial patient morbidity and mortality. The diagnosis is often established by renal biopsy. We report the results of a clinicopathological analysis of 30 patients with ANCA-associated GN who received experimental treatment with a rituximab-based regimen (patients recruited from the RITUXVAS trial). In this cohort of patients, tubulointerstitial lesions, and specifically T cell–mediated lesions, were important predictors of renal outcome, independent of baseline eGFR. Presence of B cells in the renal tissue of these patients treated with B cell–depleting therapy did not provide any independent predictor variables related to renal outcome.

Whereas the extent of tubular damage, and especially the presence of tubulitis (as evaluated on routine silver staining), was previously reported to be of prognostic value in AAV, the nature of the inflammatory cells has not been completely elucidated.<sup>21,22,25</sup> A number of studies focused on subtyping interstitial infiltrates in AAV; however, these studies did not incorporate extensive staining for B cells and plasma cells. In the interstitium, CD3+ T cells have been described as the dominant cell type, with the balance between CD4+ helper T cells and CD8+ cytotoxic T cells shifted somewhat toward the latter.<sup>26,27</sup> Furthermore, interstitial T cells (CD3+ and CD8+) have been reported to correlate significantly with serum creatinine at the time of biopsy.<sup>26,27</sup> Our data add that both tubular intraepithelial B cells (markers CD79a and CD20) and tubular intraepithelial T cells are present in biopsies of AAV patients, but that only the latter are related to impaired renal function during follow-up in patients receiving B cell–depleting therapy.

Part of the rationale behind B cell–depleting regimens in autoimmune diseases characterized by disturbances in humoral, as well as cellular, immunity comes from studies of patients with rheumatoid arthritis, which reported that T cell activation can be B cell dependent.<sup>28</sup> The hypothesis that rituximab works via inhibiting B cell/T cell interactions is supported by evidence that B cell depletion can be effective in patients who had a negative ANCA test at the start of treatment,<sup>29</sup> in whom the effector mechanism of this therapy is more likely to affect T cells.

Our data provide evidence that intraepithelial T cells in the renal biopsy are a negative predictor for renal outcome in rituximab-treated patients. Whether T cell tubulitis represents a negative predictor for all treatments or is specific to rituximab-based regimens as a result of undertreatment of T cell tubulitis is unclear. T cell tubulitis might be a precursor lesion of tubular atrophy, a parameter that we found to be

strongly related to renal outcome even after 2 years of follow-up. The proposed effector mechanism of rituximab involving inhibition of B cell/T cell interaction might be in effect in AAV patients, but other pathways might be responsible for T cell activation during rituximab treatment. For example, antigen-presenting cells other than B cells may be important in the pathogenesis of ANCA-associated GN and might explain why there can still be activation and migration of T cells into inflammatory lesions, even during B cell depletion, causing tubulointerstitial damage.

Because treatment options for renal AAV are increasing, particularly with more targeted therapies being introduced, we highlight the importance of understanding treatment effects on histopathological processes and outcomes. Although biomarkers to predict treatment response are not currently available, repeat renal biopsies in future trials would assist in the identification of markers of treatment outcome and ensure that active lesions are adequately treated.

This study is limited by its small sample size. Despite this limitation, there was a demonstrable association between tubulointerstitial lesions and renal function, highlighting their potential importance. We compared our findings to the literature on histologic predictors of renal outcome in patients receiving standard therapy. Because large numbers of biopsies of patients receiving standard therapy have previously been subjected to the same central review procedure as the RITUXVAS biopsies, data from these studies provided good comparison material.<sup>20–22</sup> However, these studies provided no comparison material for the immunostainings. Therefore, immunostained sections from the control arm of RITUXVAS were evaluated. Analyzing these slides with respect to renal outcome did not provide evidence that CD3+ T cell tubulitis is of importance in patients receiving standard treatment. However, because only 10 biopsies were available, these analyses might be underpowered and thus we cannot rule out the possibility that CD3+ T cell tubulitis is of equal importance to renal outcome in patients who receive standard therapy. Finally, for practical and ethical reasons, it was not possible to obtain protocol repeat biopsies to evaluate whether rituximab effectively depleted B cells in the renal tissue. However, B cell numbers were already low in the diagnostic biopsies obtained before the start of therapy. Renal function during follow-up was used as a surrogate outcome measure of rituximab efficacy.

In summary, intraepithelial CD3+ T cells were associated with renal outcome until 1-year follow-up. The presence of intraepithelial CD3+ T cells might be related to the development of tubular atrophy, a parameter found to be strongly related to renal outcome even after 2-year follow-up. In addition, our data demonstrate that evaluating histologic parameters next to clinical parameters in rituximab-treated patients contributes to the prediction of renal outcomes. Furthermore, although B cell–depleting regimens are promising in the treatment of AAV, some caution might be required. Whether T cell tubulitis and tubular atrophy are of greater or

equal importance in rituximab-treated patients than in patients receiving standard therapy cannot be concluded from this study. However, their predictive value justifies attention to these lesions. The extent of T cell infiltration detected on renal biopsy examination could potentially be an important factor in determining adequate therapy in individual patients, and apart from promising results with B cell-depleting therapies, attention to targeted T cell therapies might be warranted.

## CONCISE METHODS

### Patients

Patients were enrolled in the RITUXVAS trial, which is a phase II, randomized, controlled, prospective, open-label trial comparing a rituximab-based regimen with a standard cyclophosphamide-based regimen in the treatment of active, generalized (renal) AAV (protocol available at <http://www.vasculitis.org>). Forty-four patients were randomized 3:1 to a rituximab-based regimen or to current standard therapy. Patients were recruited from eight centers located in six countries: Australia, the Czech Republic, the Netherlands, Sweden, Switzerland, and the United Kingdom. Patients were eligible for inclusion in this study if they met the following criteria: were randomized to receive the rituximab-based regimen; presented with a new diagnosis of GPA, MPA, or RLV; had histologic evidence of active renal involvement; had a positive ANCA test (as determined by indirect immunofluorescence and ELISA); and provided written, informed consent.

In this study, we analyzed patients with available renal biopsies who were randomized to receive the rituximab-based regimen. The results were compared with the literature on histologic predictors of renal outcome in AAV patients treated with standard therapy because the standard therapy group in the RITUXVAS trial included only 11 patients. However, the available renal biopsies of the standard therapy group were immunostained and analyzed because this was not previously done in patients receiving standard therapy in former European Vasculitis Study Group trials and therefore no comparisons to the literature could be made.

### Treatment

Patients randomized to the rituximab group received 375 mg/m<sup>2</sup> of rituximab intravenously once weekly for 4 consecutive weeks (four doses total), as well as two doses of cyclophosphamide (15 mg/kg intravenously) administered with the first and third rituximab dose. The corticosteroid regimen consisted of 1 g of methylprednisolone intravenously, followed by daily oral corticosteroids. Maintenance therapy consisted of low-dose daily oral corticosteroids. Infusions of cyclophosphamide were administered because at the time of the study design, the therapeutic effect of rituximab was not known to be immediate. Before randomization, either plasma exchange or intravenous steroids were allowed according to local practice to treat severe organ-threatening disease manifestations, such as pulmonary hemorrhage. Modifications in therapy regimens were allowed according to protocol to treat major and minor relapses.

### Clinical Candidate Predictors and Outcome Parameters

The clinical baseline parameters under investigation were age, sex, diagnosis (GPA, MPA, RLV), and ANCA type (MPO-ANCA or PR3-ANCA). Renal function at entry was estimated by the four-variable MDRD formula,<sup>30</sup> which is commonly used and estimates GFR using the following variables: serum creatinine, age, race, and sex. Because this study included Caucasian patients, the adopted equation (for creatinine in micromoles per liter) was as follows:  $eGFR = 32,788 \times [\text{serum creatinine}]^{-1.154} \times [\text{age}]^{-0.203} \times [0.742 \text{ if female}]$ .

Renal outcome in terms of eGFR<sup>30</sup> during follow-up was the primary endpoint of this study, and eGFR was assessed at 6, 12, and 24 months of follow-up. Time to clinical remission was a secondary endpoint. Clinical remission was defined by an absence of clinical disease activity using the Birmingham Vasculitis Activity Score,<sup>31</sup> with a score of 0 for at least 2 months.

### Histologic Evaluation of Renal Biopsies

Routinely stained diagnostic renal biopsy sections were subjected to a central review procedure. Paraffin sections stained with silver, periodic acid-Schiff (PAS), hematoxylin and eosin, and trichrome were forwarded to two of five participating pathologists (I.M.B., F.F., L.H.N., R.W., J.A.B.). Two pathologists scored the biopsies independently, blinded to patient data and the scores of the other observer, and according to a previously standardized protocol.<sup>19,20</sup> Briefly, each glomerulus had to be scored separately for the presence of fibrinoid necrosis, crescents (cellular or fibrous; segmental or circumferential), sclerosis (local, segmental, or global), periglomerular infiltrates, granulomatous reactions, and any other lesion. The number of glomerular lesions was expressed as a percentage of the total number of glomeruli in a biopsy. Most interstitial, tubular, and vascular lesions were scored qualitatively (absent or present), except for interstitial infiltrates, type of cellular infiltrates (neutrophils, mononuclear cells, or eosinophils), interstitial fibrosis, and tubular atrophy, which were scored semi-quantitatively (no, mild, quite dense, or very dense interstitial infiltrates; type of cellular infiltrate not present, present, or predominantly present; no, focal, or diffuse interstitial fibrosis; and no tubular atrophy, small foci of tubular atrophy, or extensive tubular atrophy). Granulomas were scored quantitatively. In total, 39 histologic parameters were examined. Discrepancies between observers were resolved during central review sessions to achieve consensus for each biopsy.

In addition to examining the presence of single histologic parameters, biopsies were classified according to the recently developed classification schema of ANCA-associated GN.<sup>18</sup> All available biopsy specimens were included in the evaluation of single histologic parameters; however, only biopsies with a minimum of five whole glomeruli were classified.

### Immunostainings

Renal biopsy sections were immunostained for CD3, a marker for the whole T cell population; CD79a, a marker for the whole B cell population; CD20, the B cell target of rituximab; and CD138, a plasma cell marker. To assess renal morphology on immunostainings, a PAS counterstain proved successful, particularly because it enabled careful distinction between inflammatory cells located within and outside the boundaries of the tubular basement membranes.

**Table 3.** Banff 97 criteria for tubulitis, interstitial inflammation, and glomerulitis

	0	1	2	3
Tubulitis (t) <sup>a</sup>	No mononuclear cells in tubules	Foci with 1–4 cells/tubular cross-section (or 10 tubular cells)	Foci with 5–10 cells/tubular cross-section	Foci with >10 cells/tubular cross-section, or the presence of at least 2 areas of tubular basement membrane destruction accompanied by i2/i3 inflammation and t2 tubulitis elsewhere in the biopsy
Interstitial inflammation (i)	No or trivial interstitial inflammation (<10% of unscarred parenchyma)	10%–25% of the renal parenchyma is inflamed	26%–50% of the renal parenchyma is inflamed	>50% of the renal parenchyma is inflamed
Glomerulitis (g)	Absence of glomerulitis	Glomerulitis in <25% of glomeruli	Segmental/global glomerulitis in 25%–75% of glomeruli	Mostly global glomerulitis in >75% of glomeruli

<sup>a</sup>The score applies to tubules that are no more than mildly atrophic.

Paraffin-embedded sections were stained with monoclonal rabbit anti-human CD3 (Neomarkers, Fremont, CA), monoclonal mouse anti-human CD79a (DAKO, Glostrup, Denmark), monoclonal mouse anti-human CD20 (DAKO), and monoclonal mouse anti-human CD138 (Serotech, Toronto, Ontario, Canada).

Sections 4- $\mu$ m thick were deparaffinized and rehydrated. For immunostaining, sections were subjected to microwave antigen retrieval in citrate buffer (10 mM, pH 6.0, 10 minutes). Endogenous peroxidase was blocked in water containing 0.3% hydrogen peroxide for 20 minutes. Sections were incubated with rabbit anti-human CD3 (1:50), mouse anti-human CD79a (1:400), and mouse anti-human CD138 (1:200) for 1 hour at room temperature. Mouse anti-human CD20 (1:400) was incubated overnight at room temperature. All antibodies were diluted in 1% BSA in PBS. A horseradish peroxidase-labeled anti-rabbit and anti-mouse antibody (HRP Rabbit/Mouse Envision; DAKO) was incubated for 30 minutes at room temperature. The peroxidase reaction was developed with 3,3'-diaminobenzidine liquid chromogen (DAB+, 1:50; DAKO). Between each step, sections were rinsed with PBS. Sections were then counterstained with PAS. As a last step, all sections were dehydrated once again using increasing ethanol concentrations, ending in a xylol bath.

All immunostained slides were scored according to the Banff 97 criteria for tubulitis, interstitial inflammation and glomerulitis (Table 3).<sup>23</sup> Glomerulitis was defined as the presence of intraglomerular inflammatory cells (mononuclear cells, PMNs).

### Statistical Analyses

Spearman's rank correlation coefficient was calculated to determine associations of continuous clinical and histologic parameters with renal function at set time points. The choice of the Spearman's rank as opposed to the Pearson's correlation coefficient was based on data distribution. The nonparametric Mann–Whitney *U* test or Kruskal–Wallis test was performed to assess differences in renal function according to clinical and histologic subgroups. Univariate linear regression analyses were performed to assess the predictive value of baseline renal function to renal outcome during follow-up. Backward stepwise multiple linear regression analysis was performed to develop a model of independent predictors of renal function at

1 year of follow-up. Baseline parameters that correlated with renal function at 1 year in univariate analyses ( $P < 0.10$ ) were considered candidate predictors for entry in the multiple model. The following candidate predictors were included in the regression analysis: baseline eGFR, patient age at entry, percentage of normal glomeruli, percentage of globally sclerosed glomeruli, percentage of glomeruli with fibrous crescents, CD3+ T cell tubulitis (Banff 97 score), tubular atrophy, and interstitial fibrosis. Dummy variables were created for the semi-quantitative parameters tubular atrophy and interstitial fibrosis. The reference categories were absence of fibrosis or tubular atrophy. No interactions were considered. The *P* value of the covariates was set at 0.10 for removal in the multiple linear regression model. The final model for the 12-month data was repeated for the 24-month data to assess whether the same parameters held their effect size.

Analyses were performed using the SPSS statistical software package for Windows (version 16.0; SPSS Inc, Chicago, IL). The 5% level of confidence was taken to indicate statistical significance. All tests were two tailed.

### ACKNOWLEDGMENTS

We thank Mrs. Dorothy Walsh, Dr. Chen Au Peh, Dr. James Nolan, Dr. Pieter van Paassen, Dr. T.B.J. Demeyere, Dr. Jan Willem Cohen Tervaert, Dr. Raashid Luqmani, Dr. Thomas Hauser, Dr. Meryl Griffiths, Dr. Matthew Morgan, Dr. Caroline Savage, Dr. Vladimír Tesař, Dr. Eva Honsová, and Dr. Mårten Segelmark for including patients and for their help in retrieving renal biopsy material.

M.W. is supported by a RCT Mentoring Award from the Canadian Institute of Health Research.

This study was presented in part at the annual meeting of the American Society of Nephrology, November 4–9, 2008, Philadelphia, Pennsylvania, as well as at the 14th International Vasculitis and ANCA Workshop, June 6–9, 2009, Lund, Sweden, and Copenhagen, Denmark, and has been published in part in abstract form.

## DISCLOSURES

None.

## REFERENCES

- Hoffman GS, Kerr GS, Leavitt RY, Hallahan CW, Lebovics RS, Travis WD, Rottem M, Fauci AS: Wegener granulomatosis: An analysis of 158 patients. *Ann Intern Med* 116: 488–498, 1992
- Little MA, Nightingale P, Verburgh CA, Hauser T, De Groot K, Savage C, Jayne D, Harper L; European Vasculitis Study (EUVAS) Group: Early mortality in systemic vasculitis: Relative contribution of adverse events and active vasculitis. *Ann Rheum Dis* 69: 1036–1043, 2010
- Brihaye B, Aouba A, Pagnoux C, Cohen P, Lacassin F, Guillevin L: Adjunction of rituximab to steroids and immunosuppressants for refractory/relapsing Wegener's granulomatosis: A study on 8 patients. *Clin Exp Rheumatol* 25[Suppl 44]: S23–S27, 2007
- Eriksson P: Nine patients with anti-neutrophil cytoplasmic antibody-positive vasculitis successfully treated with rituximab. *J Intern Med* 257: 540–548, 2005
- Ferraro AJ, Day CJ, Drayson MT, Savage CO: Effective therapeutic use of rituximab in refractory Wegener's granulomatosis. *Nephrol Dial Transplant* 20: 622–625, 2005
- Keogh KA, Wylam ME, Stone JH, Specks U: Induction of remission by B lymphocyte depletion in eleven patients with refractory antineutrophil cytoplasmic antibody-associated vasculitis. *Arthritis Rheum* 52: 262–268, 2005
- Keogh KA, Ytterberg SR, Fervenza FC, Carlson KA, Schroeder DR, Specks U: Rituximab for refractory Wegener's granulomatosis: Report of a prospective, open-label pilot trial. *Am J Respir Crit Care Med* 173: 180–187, 2006
- Omdal R, Wildhagen K, Hansen T, Gunnarsson R, Kristoffersen G: Anti-CD20 therapy of treatment-resistant Wegener's granulomatosis: Favourable but temporary response. *Scand J Rheumatol* 34: 229–232, 2005
- Smith KG, Jones RB, Burns SM, Jayne DR: Long-term comparison of rituximab treatment for refractory systemic lupus erythematosus and vasculitis: Remission, relapse, and re-treatment. *Arthritis Rheum* 54: 2970–2982, 2006
- Stasi R, Stipa E, Del Poeta G, Amadori S, Newland AC, Provan D: Long-term observation of patients with anti-neutrophil cytoplasmic antibody-associated vasculitis treated with rituximab. *Rheumatology (Oxford)* 45: 1432–1436, 2006
- Tamura N, Matsudaira R, Hirashima M, Ikeda M, Tajima M, Nawata M, Morimoto S, Kaneda K, Kobayashi S, Hashimoto H, Takasaki Y: Two cases of refractory Wegener's granulomatosis successfully treated with rituximab. *Intern Med* 46: 409–414, 2007
- Jones RB, Ferraro AJ, Chaudhry AN, Brogan P, Salama AD, Smith KG, Savage CO, Jayne DR: A multicenter survey of rituximab therapy for refractory antineutrophil cytoplasmic antibody-associated vasculitis. *Arthritis Rheum* 60: 2156–2168, 2009
- Jones RB, Tervaert JW, Hauser T, Luqmani R, Morgan MD, Peh CA, Savage CO, Segelmark M, Tesar V, van Paassen P, Walsh D, Walsh M, Westman K, Jayne DR European Vasculitis Study Group: Rituximab versus cyclophosphamide in ANCA-associated renal vasculitis. *N Engl J Med* 363: 211–220, 2010
- Stone JH, Merkel PA, Spiera R, Seo P, Langford CA, Hoffman GS, Kallenberg CG, St Clair EW, Turkiewicz A, Tchao NK, Webber L, Ding L, Sejismundo LP, Mieras K, Weitzkamp D, Ikle D, Seyfert-Margolis V, Mueller M, Brunetta P, Allen NB, Fervenza FC, Geetha D, Keogh KA, Kissin EY, Monach PA, Peikert T, Stegeman C, Ytterberg SR, Specks U RAVE-ITN Research Group: Rituximab versus cyclophosphamide for ANCA-associated vasculitis. *N Engl J Med* 363: 221–232, 2010
- Falk RJ, Gross WL, Guillevin L, Hoffman GS, Jayne DR, Jennette JC, Kallenberg CG, Luqmani R, Mahr AD, Matteson EL, Merkel PA, Specks U, Watts RA American College of Rheumatology/American Society of Nephrology/European League Against Rheumatism: Granulomatosis with polyangiitis (Wegener's): An alternative name for Wegener's granulomatosis. *Arthritis Rheum* 63: 863–864, 2011
- Falk RJ, Gross WL, Guillevin L, Hoffman G, Jayne DR, Jennette JC, Kallenberg CG, Luqmani R, Mahr AD, Matteson EL, Merkel PA, Specks U, Watts R: Granulomatosis with polyangiitis (Wegener's): An alternative name for Wegener's granulomatosis. *Ann Rheum Dis* 70: 704, 2011
- Falk RJ, Gross WL, Guillevin L, Hoffman G, Jayne DR, Jennette JC, Kallenberg CG, Luqmani R, Mahr AD, Matteson EL, Merkel PA, Specks U, Watts R: Granulomatosis with polyangiitis (Wegener's): An alternative name for Wegener's granulomatosis. *J Am Soc Nephrol* 22: 587–588, 2011
- Berden AE, Ferrario F, Hagen EC, Jayne DR, Jennette JC, Joh K, Neumann I, Noël LH, Pusey CD, Waldherr R, Bruijn JA, Bajema IM: Histopathologic classification of ANCA-associated glomerulonephritis. *J Am Soc Nephrol* 21: 1628–1636, 2010
- Bajema IM, Hagen EC, Hansen BE, Hermans J, Noël LH, Waldherr R, Ferrario F, van der Woude FJ, Bruijn JA: The renal histopathology in systemic vasculitis: An international survey study of inter- and intra-observer agreement. *Nephrol Dial Transplant* 11: 1989–1995, 1996
- Bajema IM, Hagen EC, Hermans J, Noël LH, Waldherr R, Ferrario F, Van Der Woude FJ, Bruijn JA: Kidney biopsy as a predictor for renal outcome in ANCA-associated necrotizing glomerulonephritis. *Kidney Int* 56: 1751–1758, 1999
- Hauer HA, Bajema IM, Van Houwelingen HC, Ferrario F, Noël LH, Waldherr R, Jayne DR, Rasmussen N, Bruijn JA, Hagen EC European Vasculitis Study Group (EUVAS): Determinants of outcome in ANCA-associated glomerulonephritis: A prospective clinico-histopathological analysis of 96 patients. *Kidney Int* 62: 1732–1742, 2002
- de Lind van Wijngaarden RA, Hauer HA, Wolterbeek R, Jayne DR, Gaskin G, Rasmussen N, Noël LH, Ferrario F, Waldherr R, Hagen EC, Bruijn JA, Bajema IM European Vasculitis Study Group (EUVAS): Clinical and histologic determinants of renal outcome in ANCA-associated vasculitis: A prospective analysis of 100 patients with severe renal involvement. *J Am Soc Nephrol* 17: 2264–2274, 2006
- Racusen LC, Solez K, Colvin RB, Bonsib SM, Castro MC, Cavallo T, Croker BP, Demetris AJ, Drachenberg CB, Fogo AB, Furness P, Gaber LW, Gibson IW, Glotz D, Goldberg JC, Grande J, Halloran PF, Hansen HE, Hartley B, Hayry PJ, Hill CM, Hoffman EO, Hunsicker LG, Lindblad AS, Yamaguchi Y, Mihatsch MJ, Nadasdy T, Nickerson P, Olsen TS, Papadimitriou JC, Randhawa PS, Rayner DC, Roberts I, Rose S, Rush D, Salinas-Madrigal L, Salomon DR, Sund S, Taskinen E, Trpkov K, Yamaguchi Y: The Banff 97 working classification of renal allograft pathology. *Kidney Int* 55: 713–723, 1999
- Mukhtyar C, Flossmann O, Hellmich B, Bacon P, Cid MC, Cohen-Tervaert JW, Gross WL, Guillevin L, Jayne D, Mahr A, Merkel PA, Raspe H, Scott D, Witter J, Yazici H, Luqmani RA European Vasculitis Study Group (EUVAS): Outcomes from studies of antineutrophil cytoplasmic antibody associated vasculitis: A systematic review by the European League Against Rheumatism systemic vasculitis task force. *Ann Rheum Dis* 67: 1004–1010, 2008
- Vergunst CE, van Gorp E, Hagen EC, van Houwelingen HC, Hauer HA, Noël LH, Waldherr R, Ferrario F, van der Woude FJ, Bruijn JA, Bajema IM EC/BCR Project for ANCA-Assay Standardisation: An index for renal outcome in ANCA-associated glomerulonephritis. *Am J Kidney Dis* 41: 532–538, 2003
- Weidner S, Carl M, Riess R, Rupperecht HD: Histologic analysis of renal leukocyte infiltration in antineutrophil cytoplasmic antibody-associated vasculitis: Importance of monocyte and neutrophil infiltration in tissue damage. *Arthritis Rheum* 50: 3651–3657, 2004
- Aasarød K, Bostad L, Hammerstrøm J, Jørstad S, Iversen BM: Wegener's granulomatosis: Inflammatory cells and markers of repair and



- fibrosis in renal biopsies—A clinicopathological study. *Scand J Urol Nephrol* 35: 401–410, 2001
28. Takemura S, Klimiuk PA, Braun A, Goronzy JJ, Weyand CM: T cell activation in rheumatoid synovium is B cell dependent. *J Immunol* 167: 4710–4718, 2001
  29. Seo P, Specks U, Keogh KA: Efficacy of rituximab in limited Wegener's granulomatosis with refractory granulomatous manifestations. *Clin Exp Rheumatol* 25: S-111, 2007
  30. Levey AS, Bosch JP, Lewis JB, Greene T, Rogers N, Roth D Modification of Diet in Renal Disease Study Group: A more accurate method to estimate glomerular filtration rate from serum creatinine: A new prediction equation. *Ann Intern Med* 130: 461–470, 1999
  31. Luqmani RA, Bacon PA, Moots RJ, Janssen BA, Pall A, Emery P, Savage C, Adu D: Birmingham Vasculitis Activity Score (BVAS) in systemic necrotizing vasculitis. *QJM* 87: 671–678, 1994